

Correlation
Histopathology and Clinical Presentations:

II. Histologic Images A to K

Verena K. Affolter

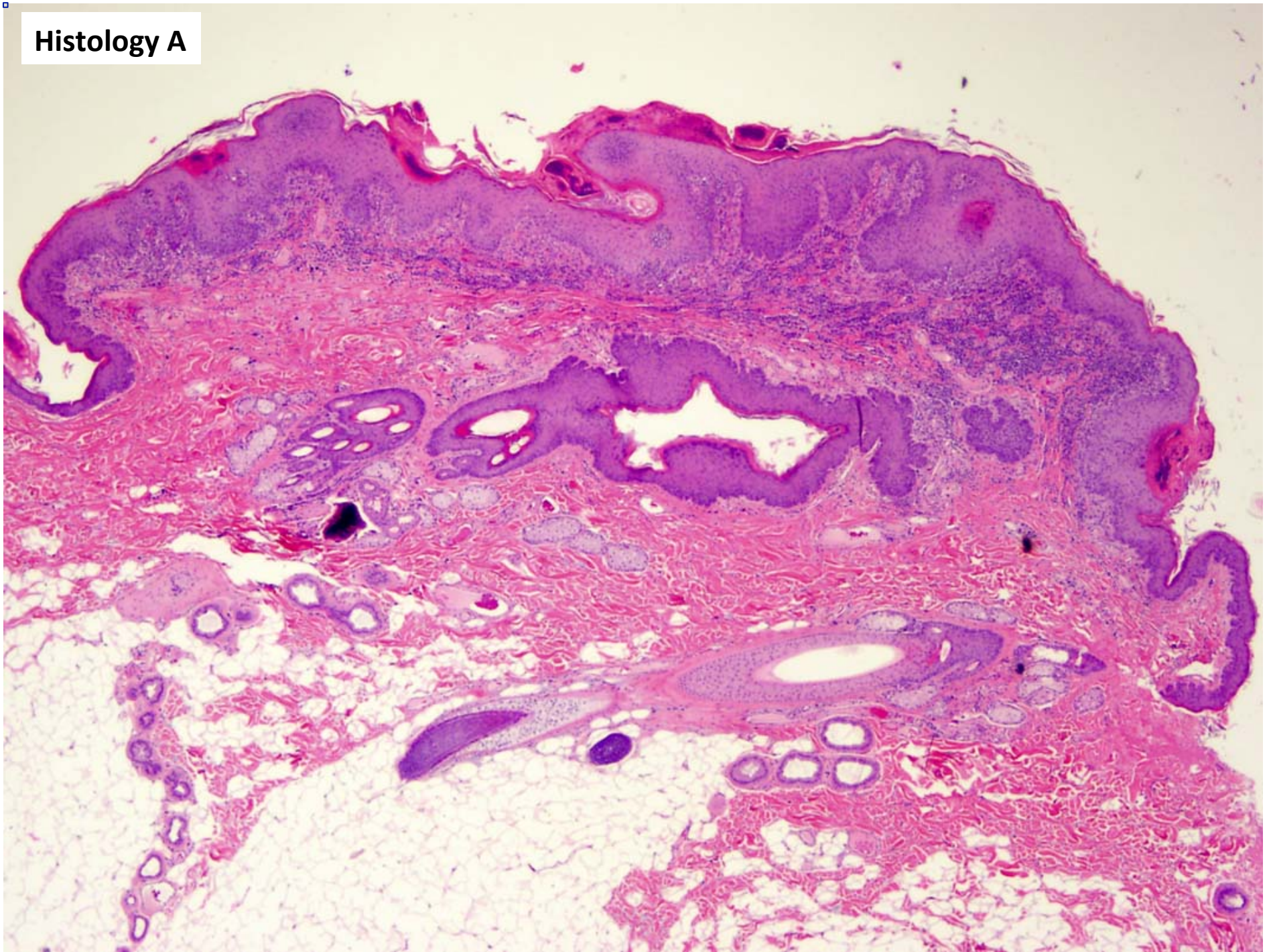
NAVDF - ISVD

Saturday, April 12, 11am – 12.30pm

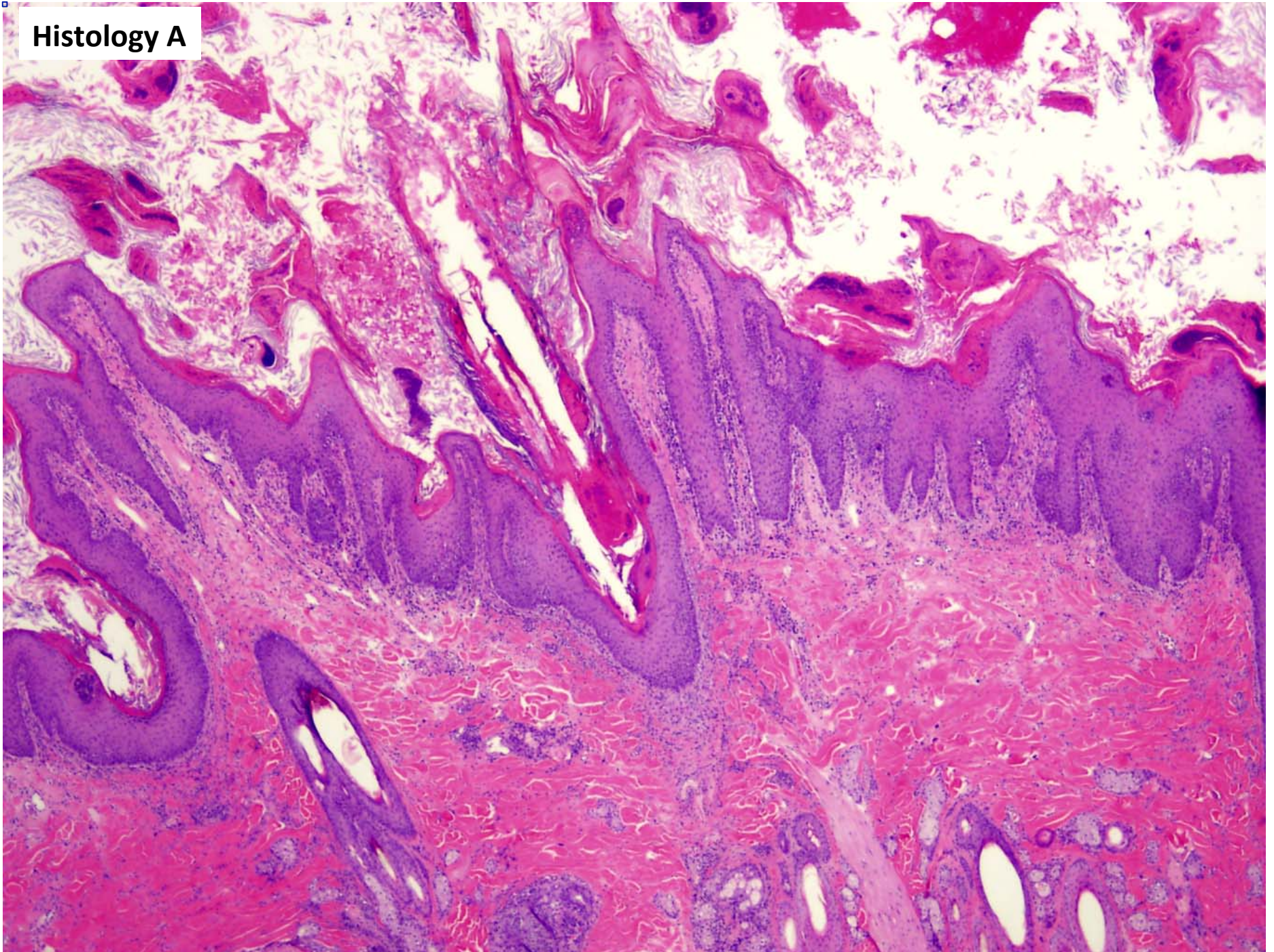
Goal

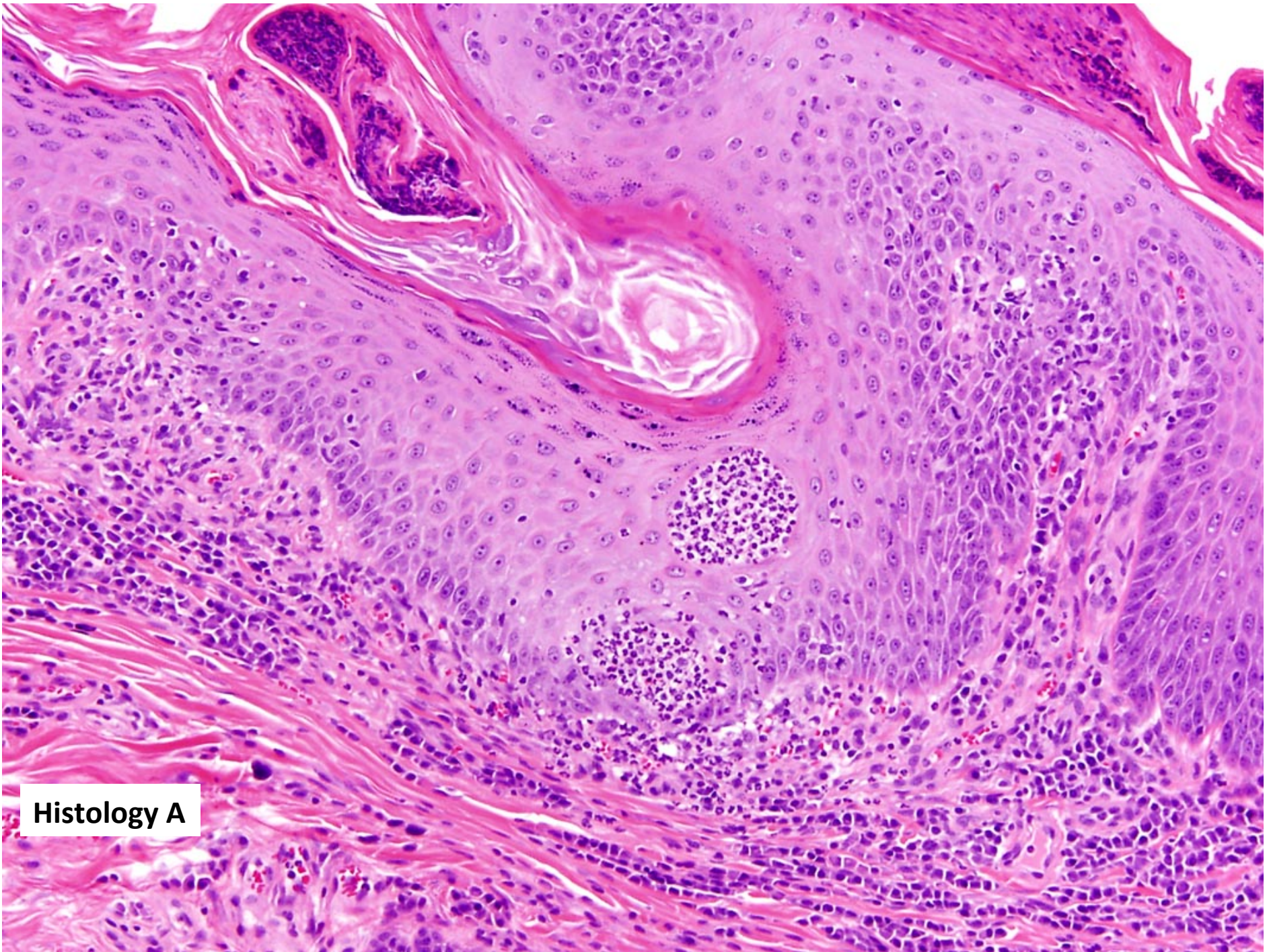
1. Match histologic pictures A to K with histopathologic reports 1 to 10
2. Formulate a morphologic diagnosis
3. List possible clinical lesions associated with the histologic changes

Histology A



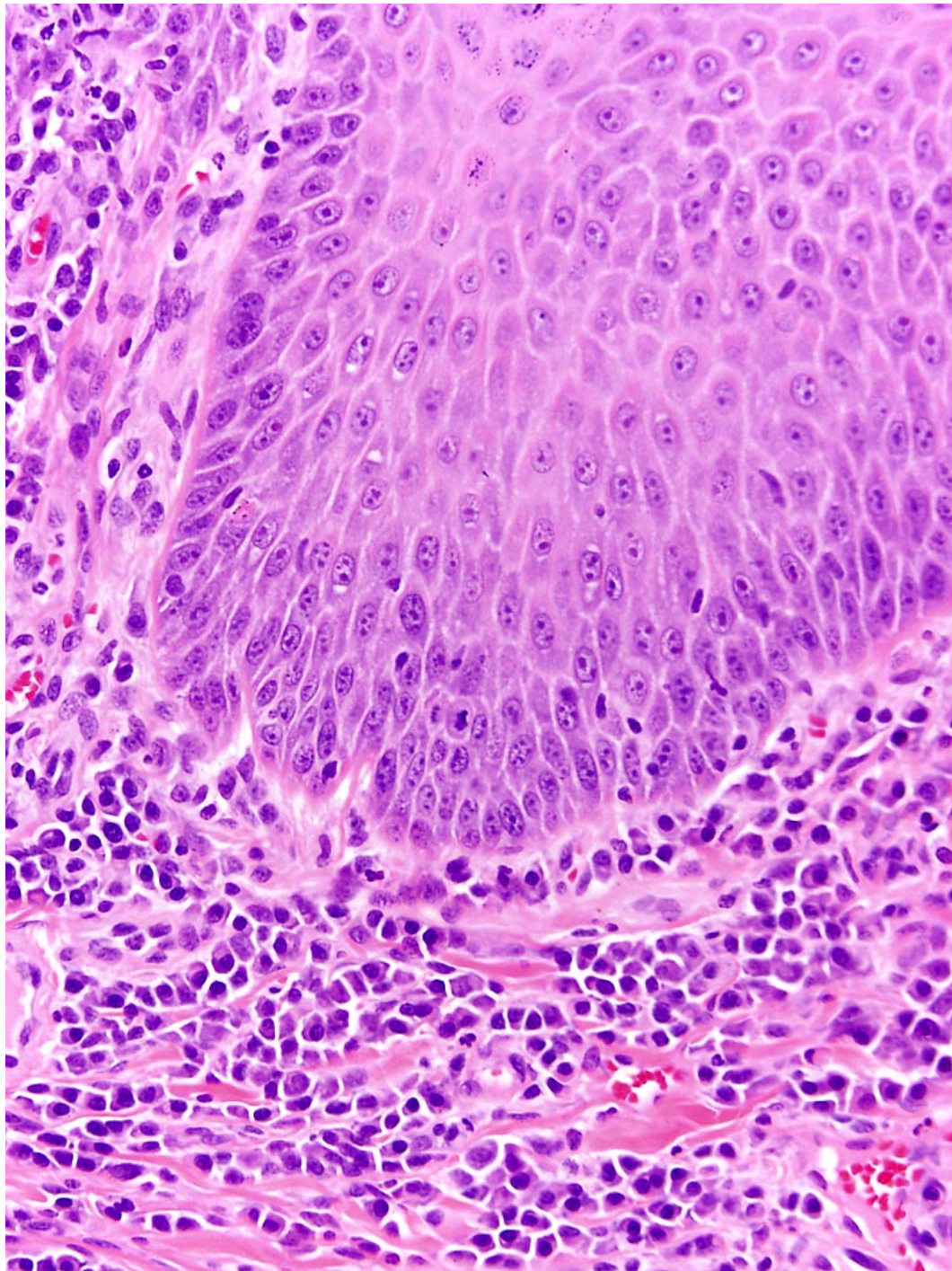
Histology A



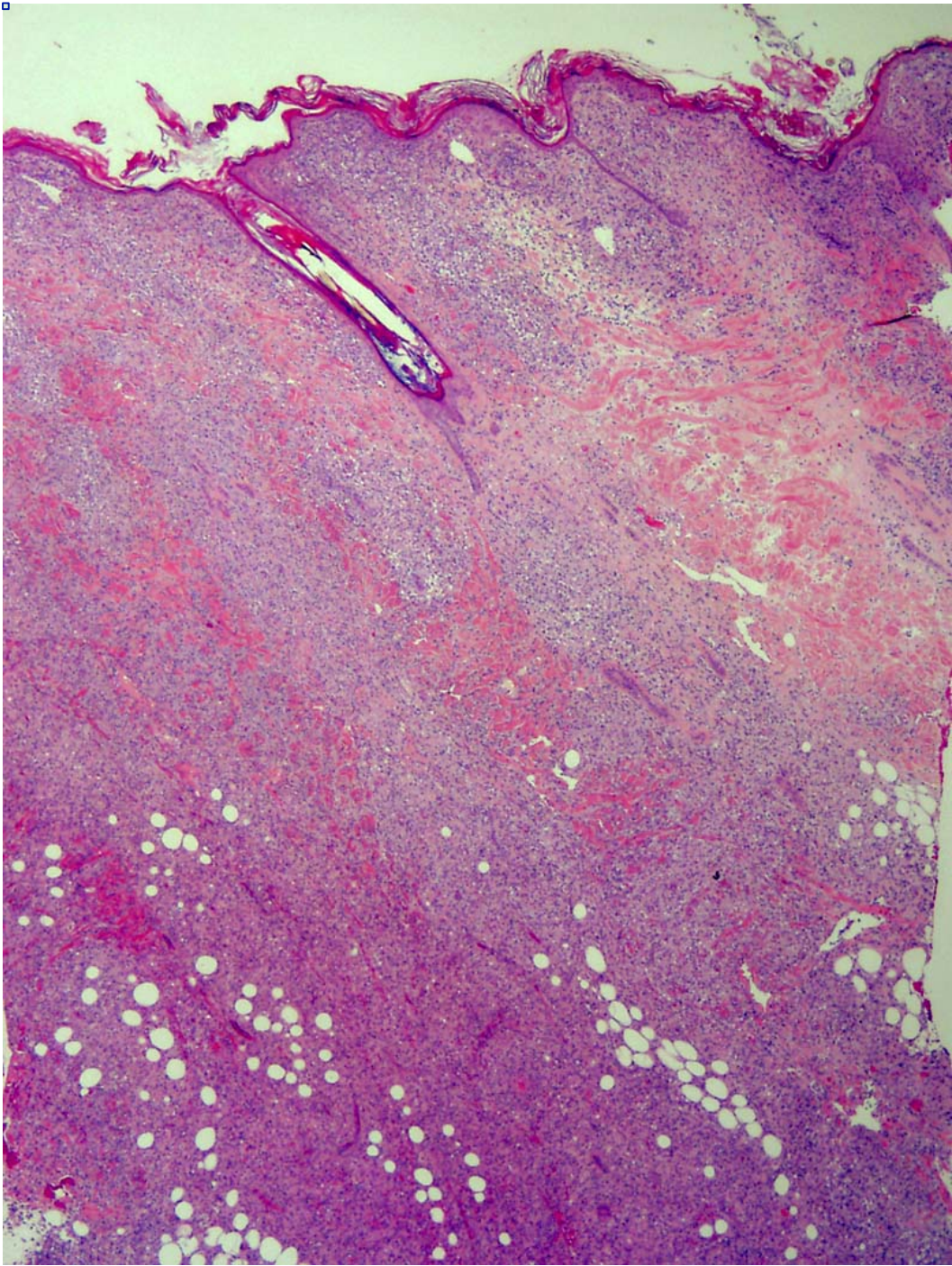


Histology A

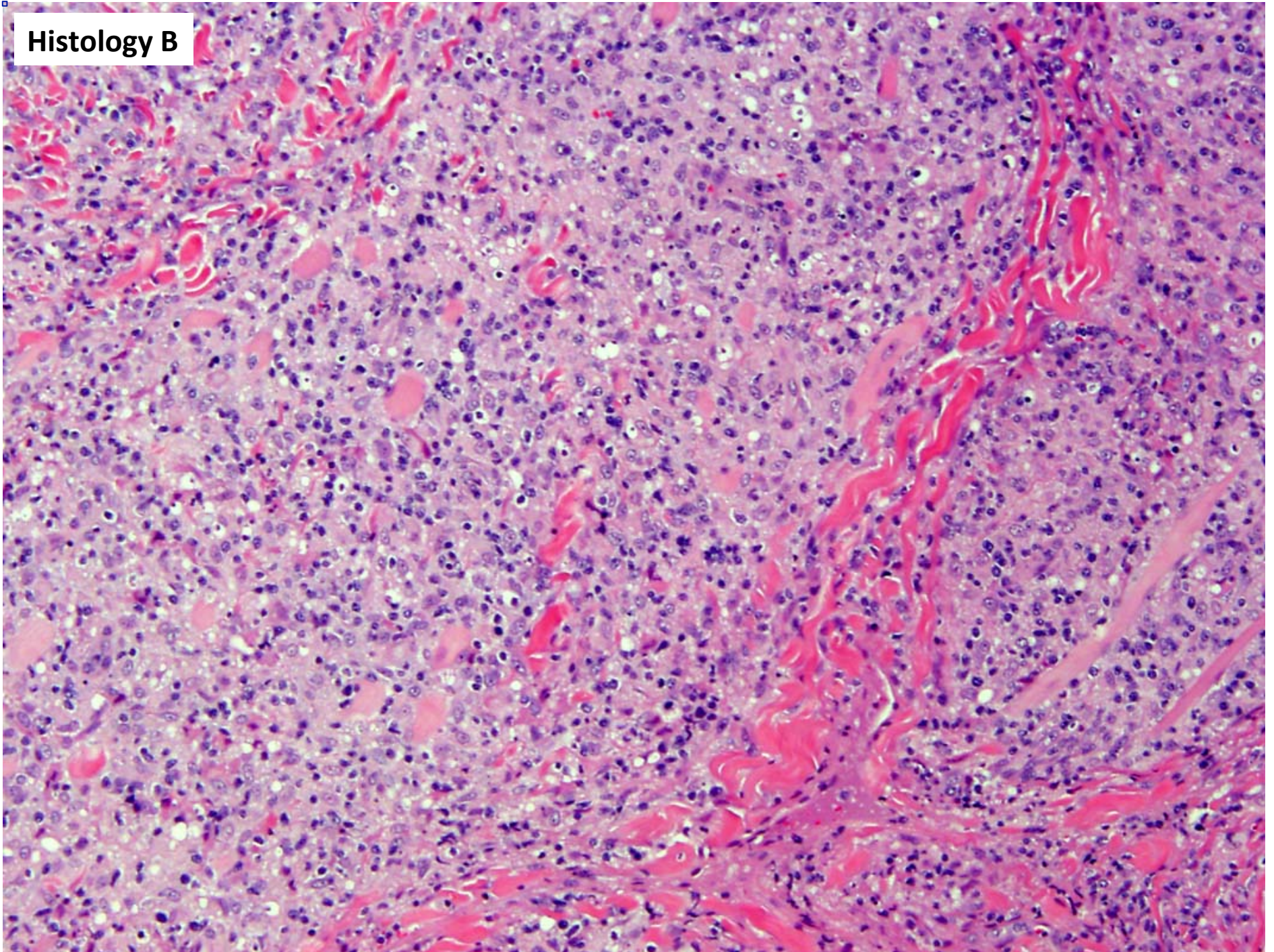
Histology A



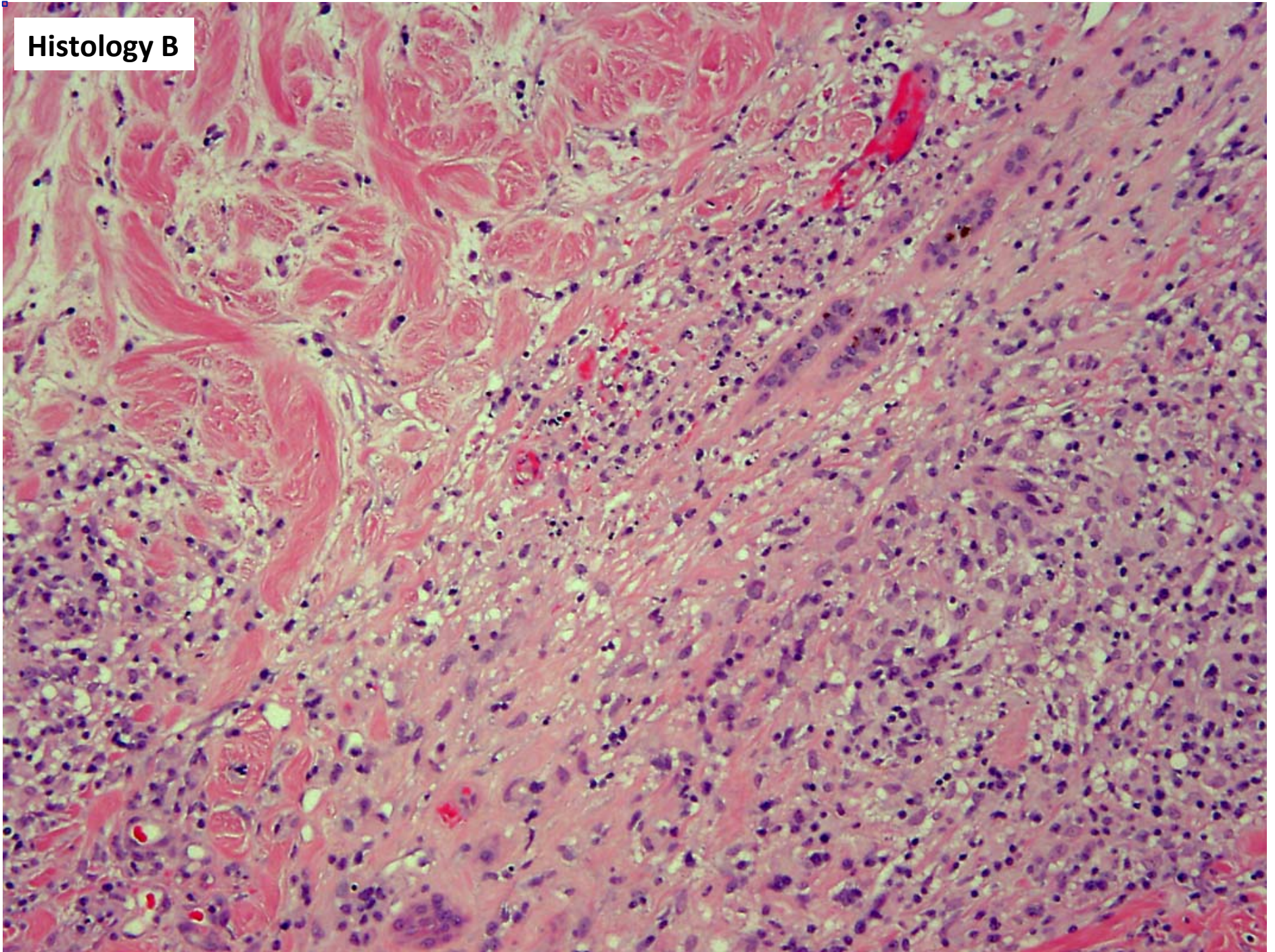
Histology B



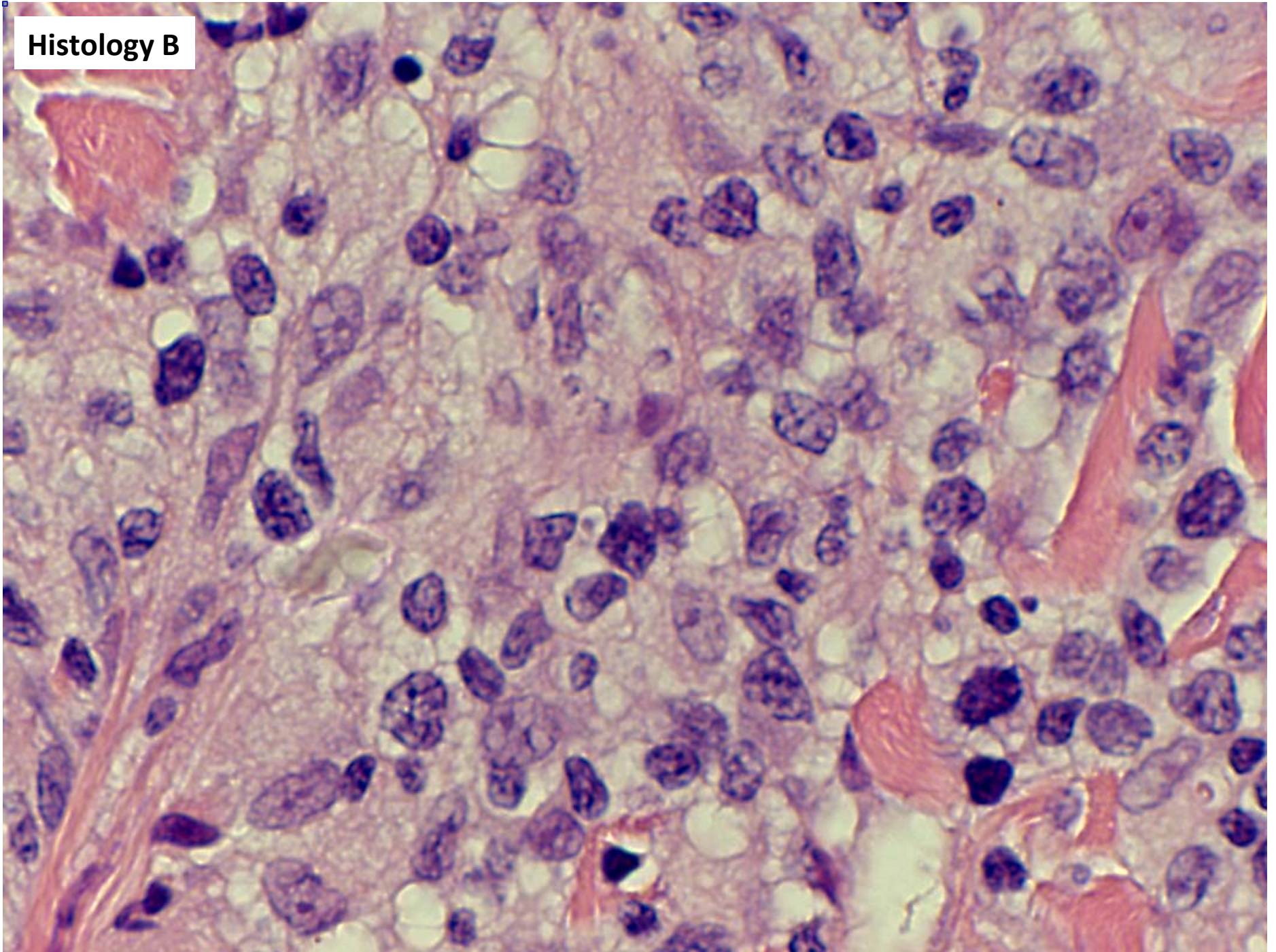
Histology B



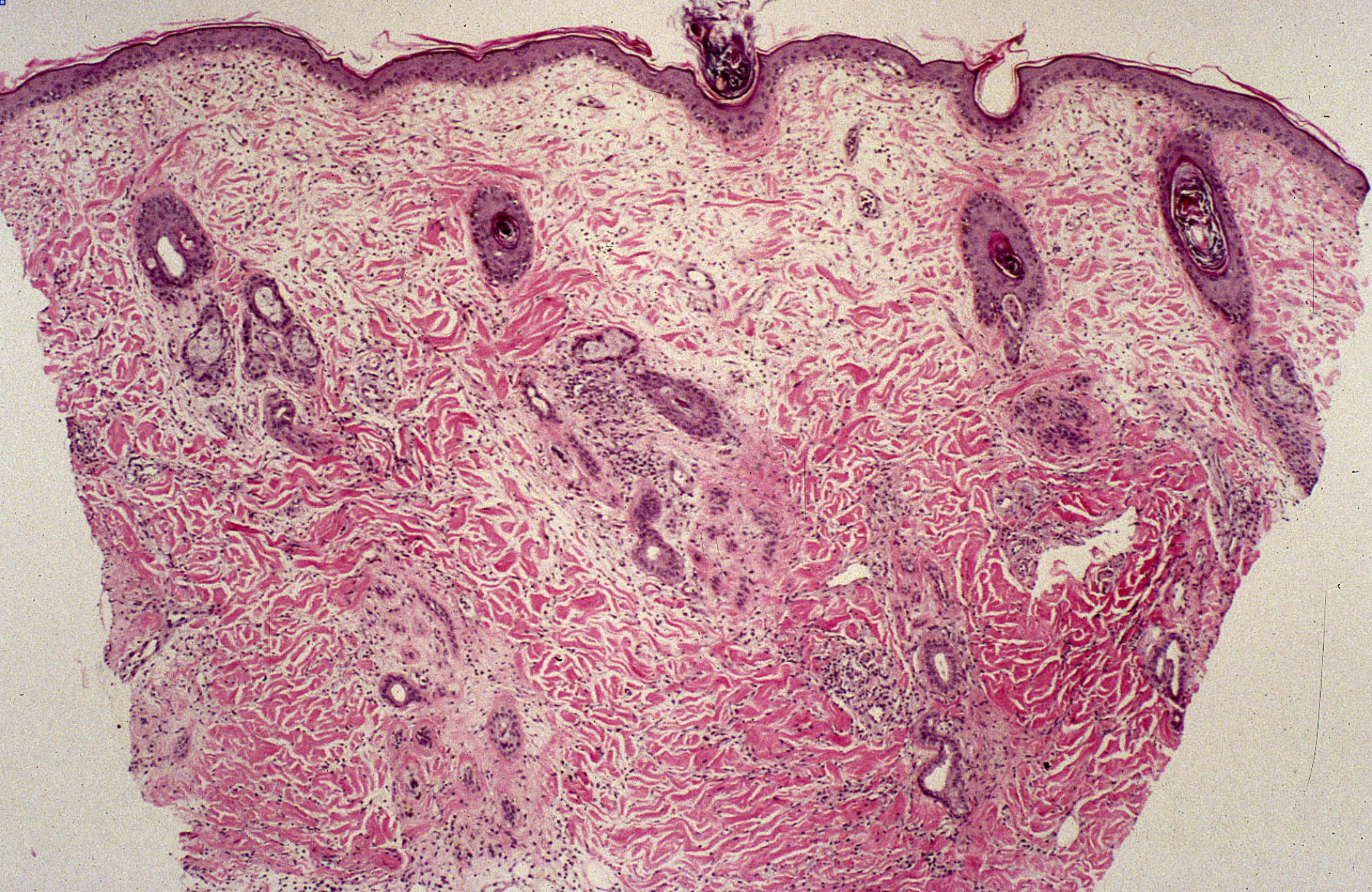
Histology B



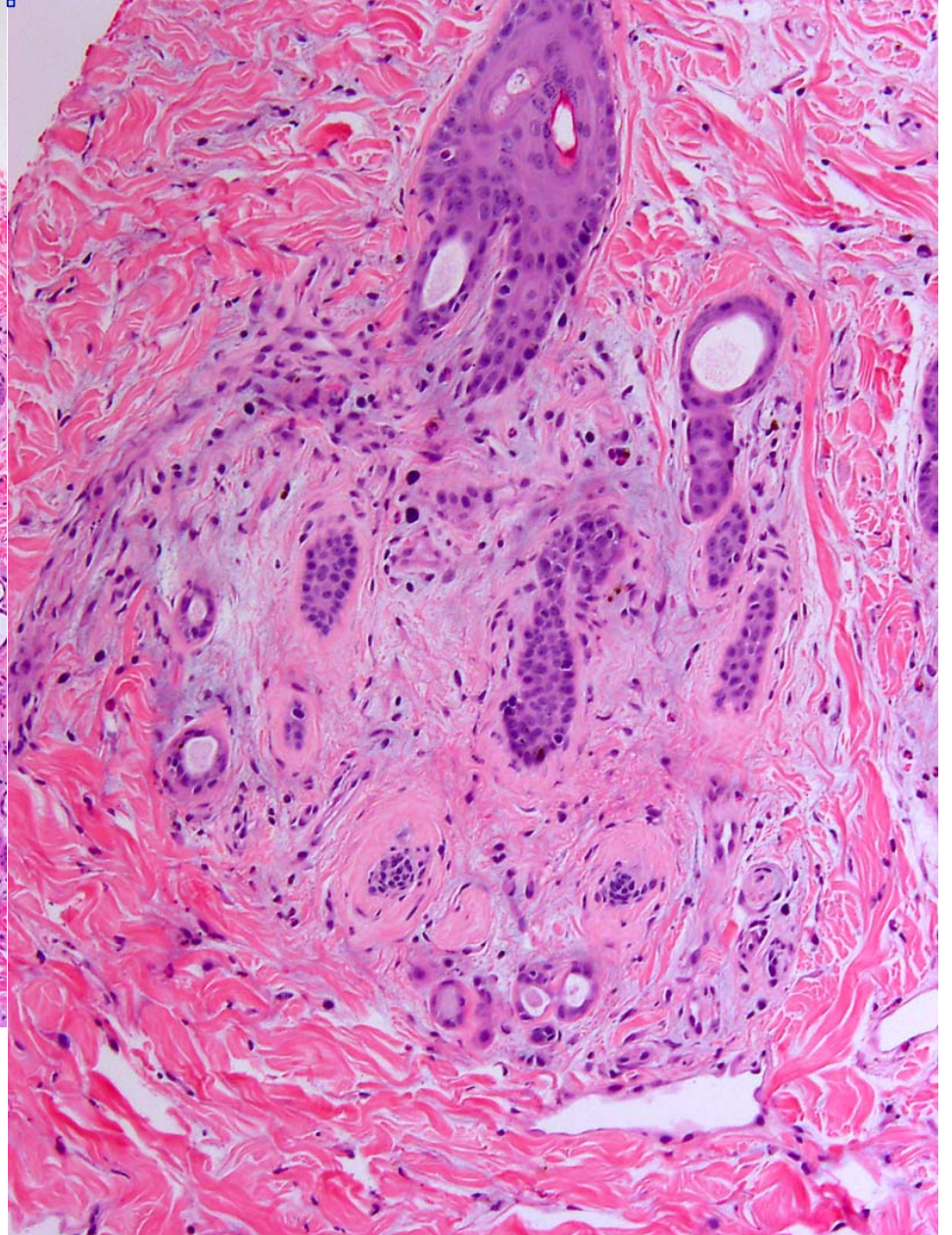
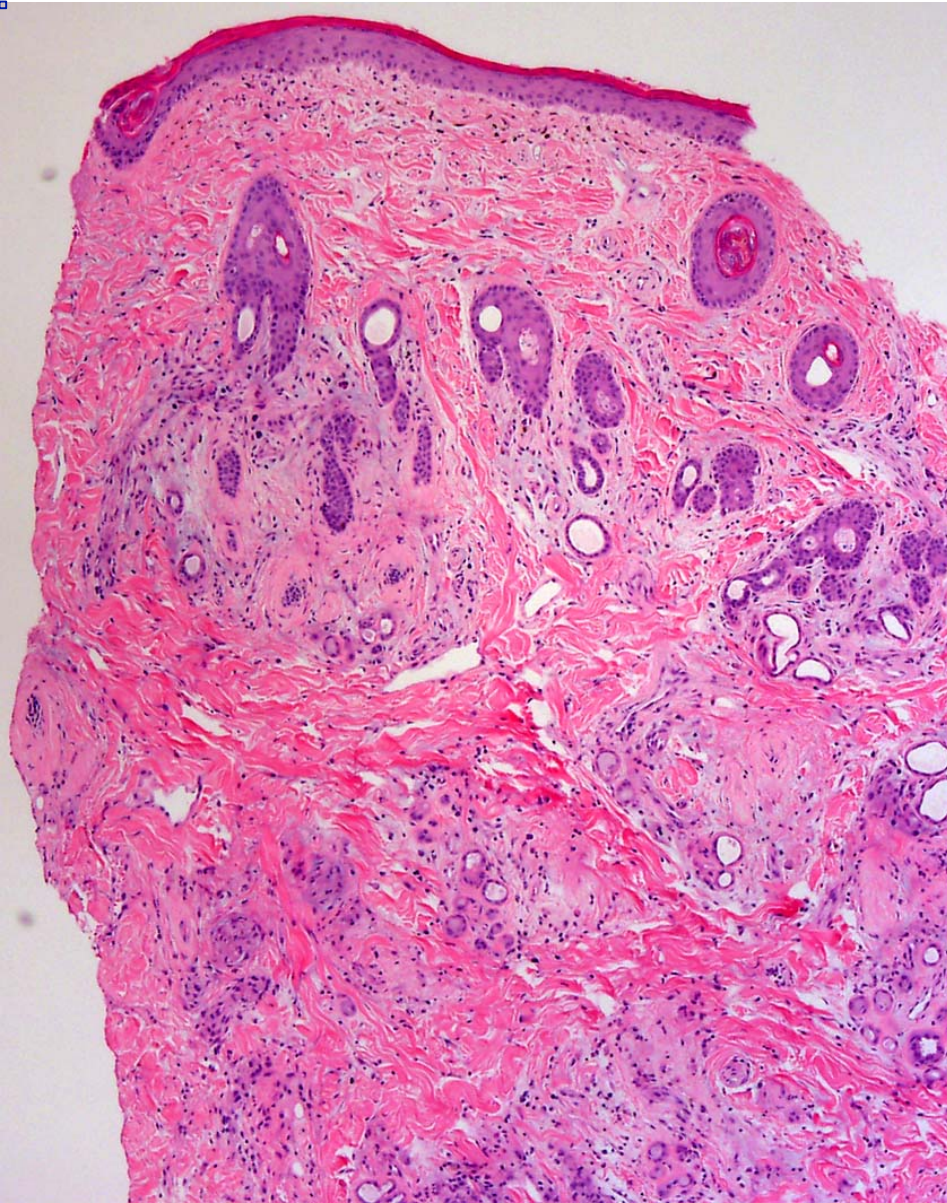
Histology B

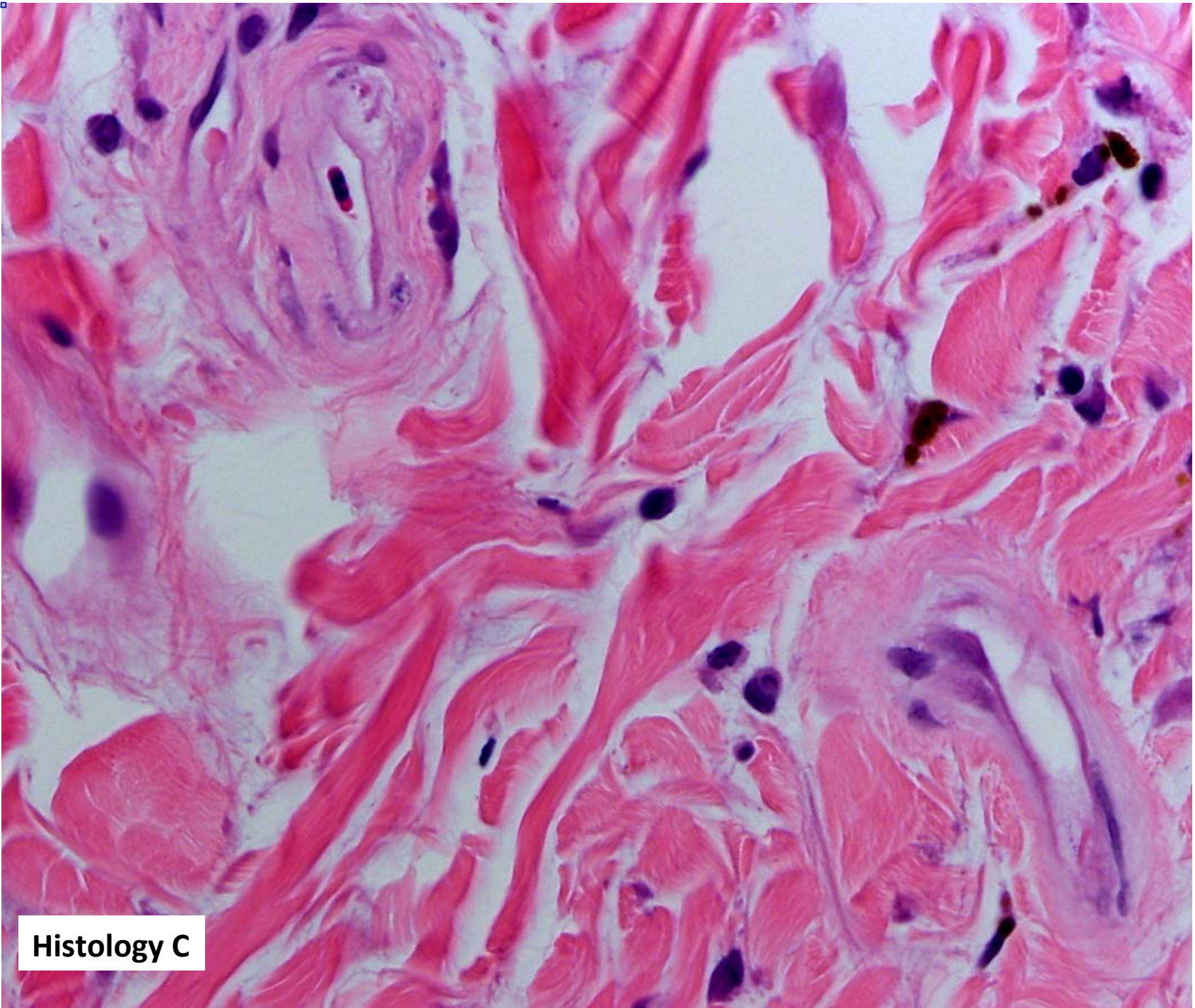


Histology C



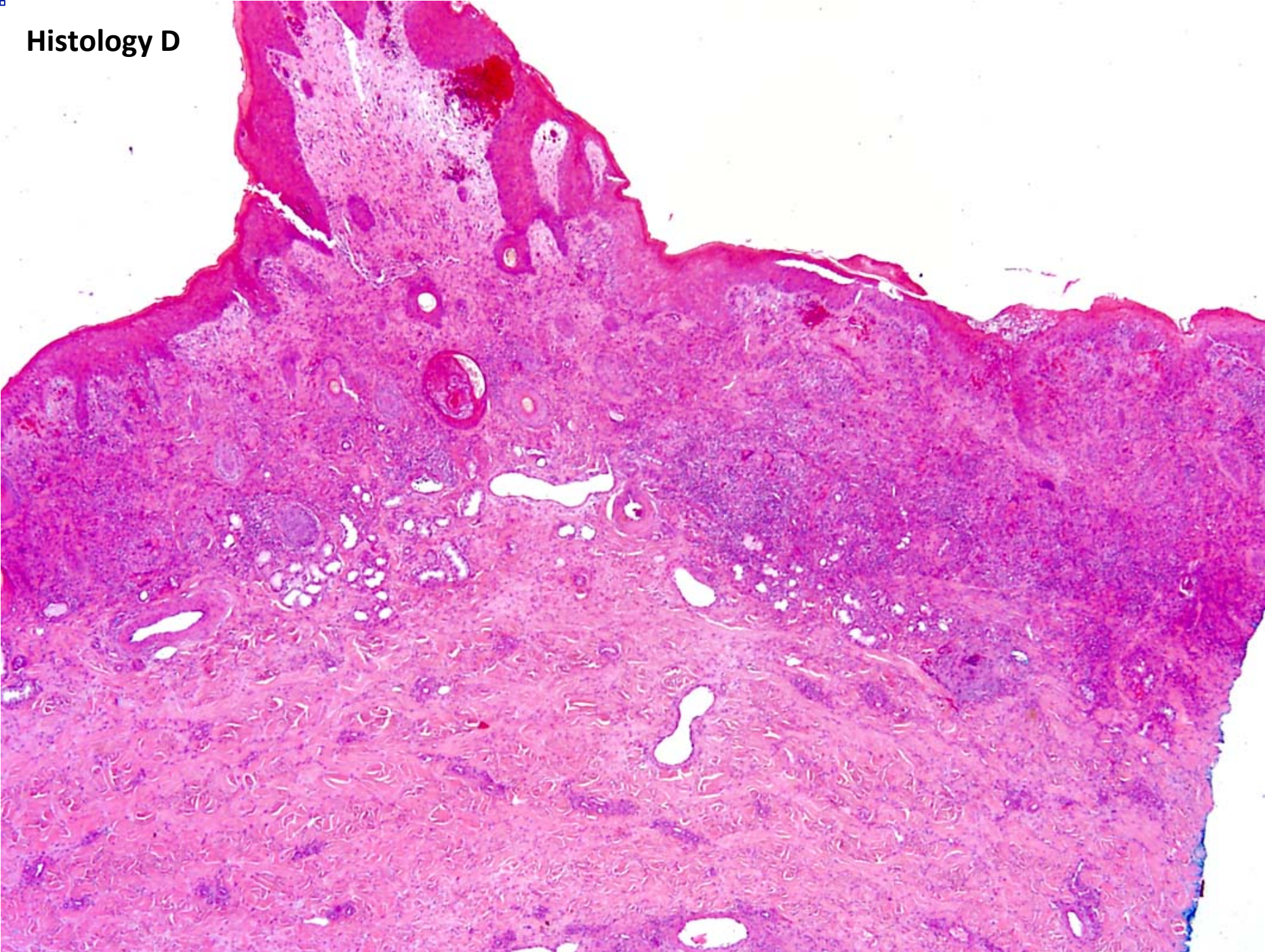
Histology C



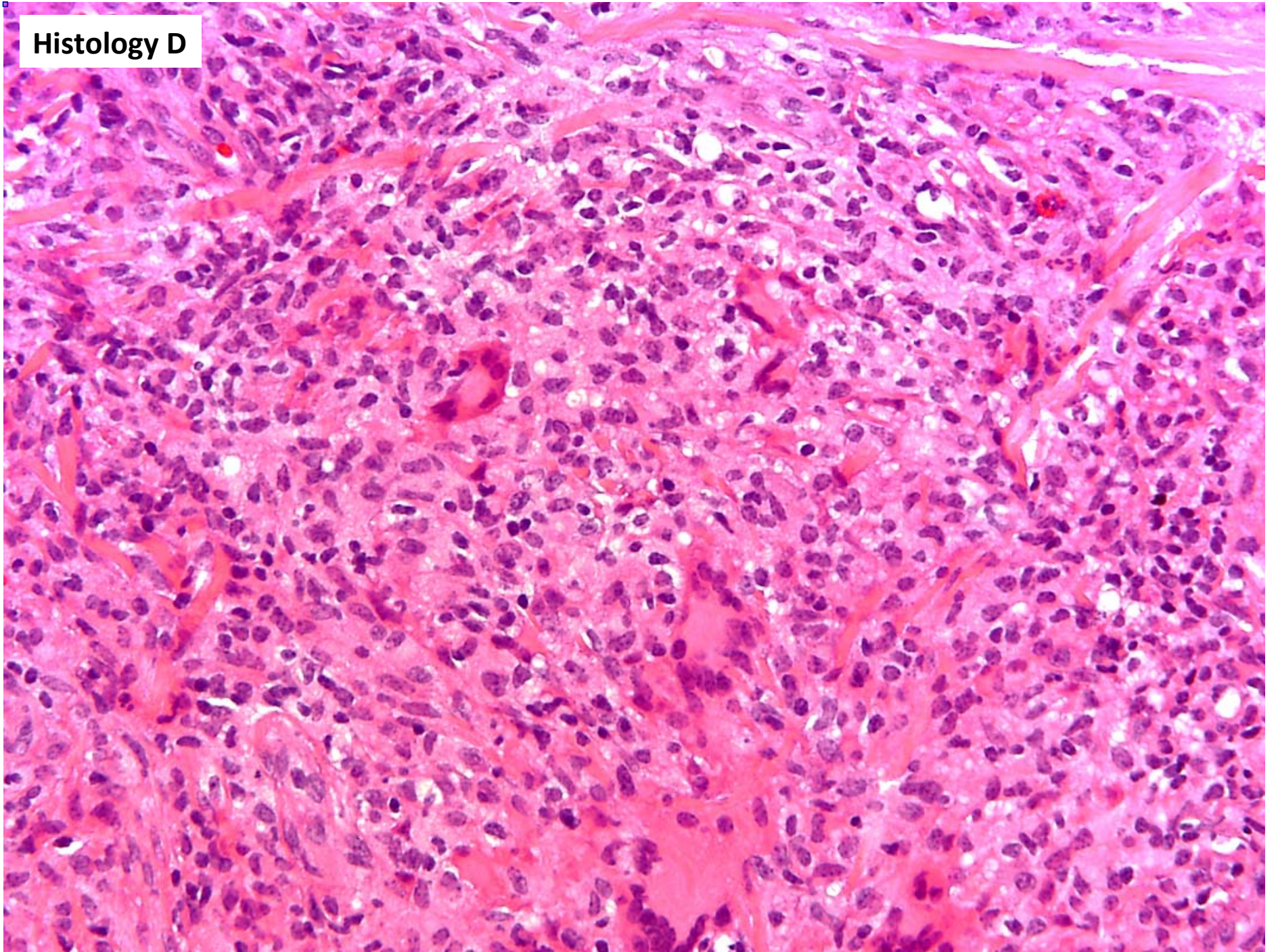


Histology C

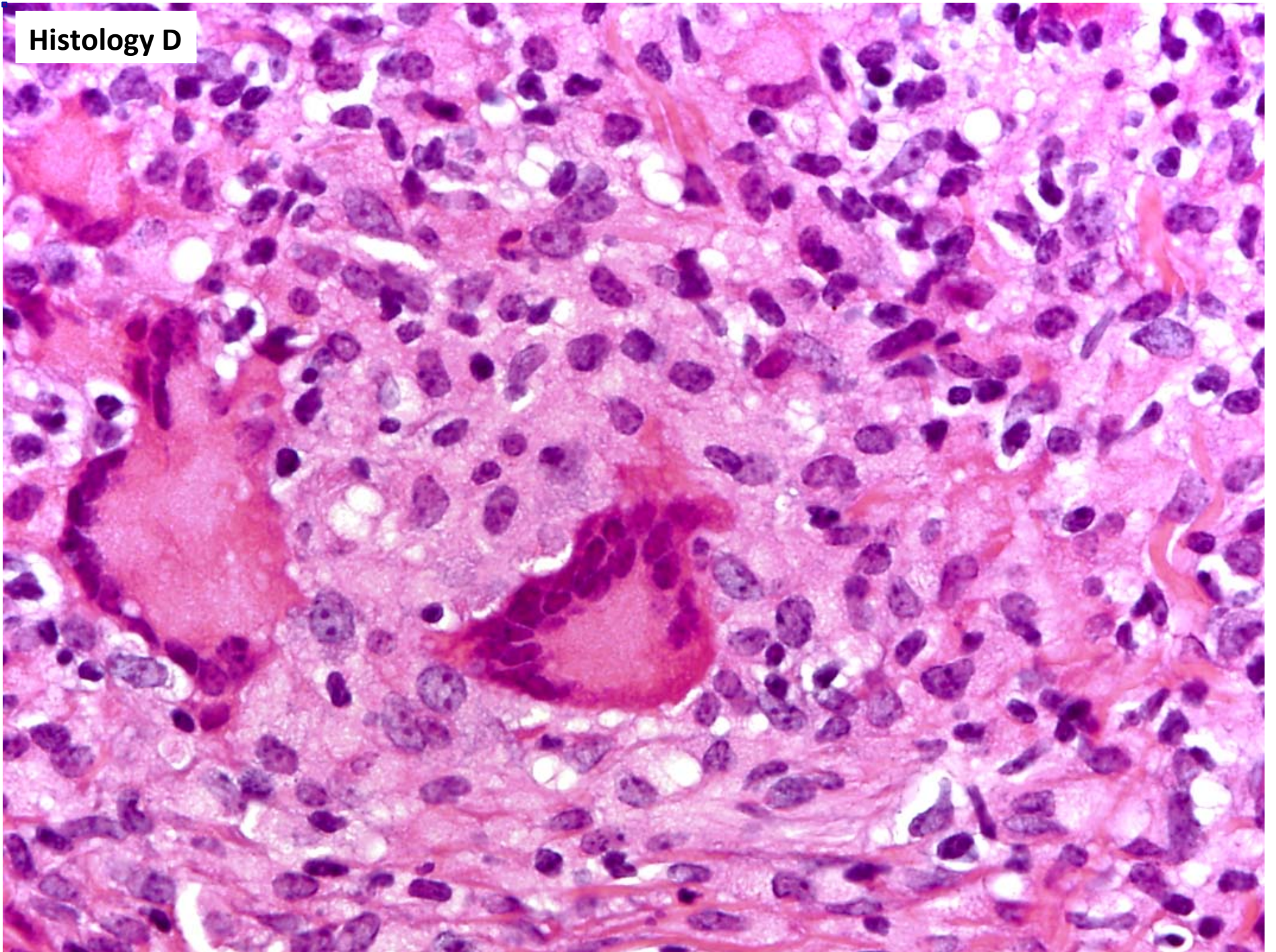
Histology D



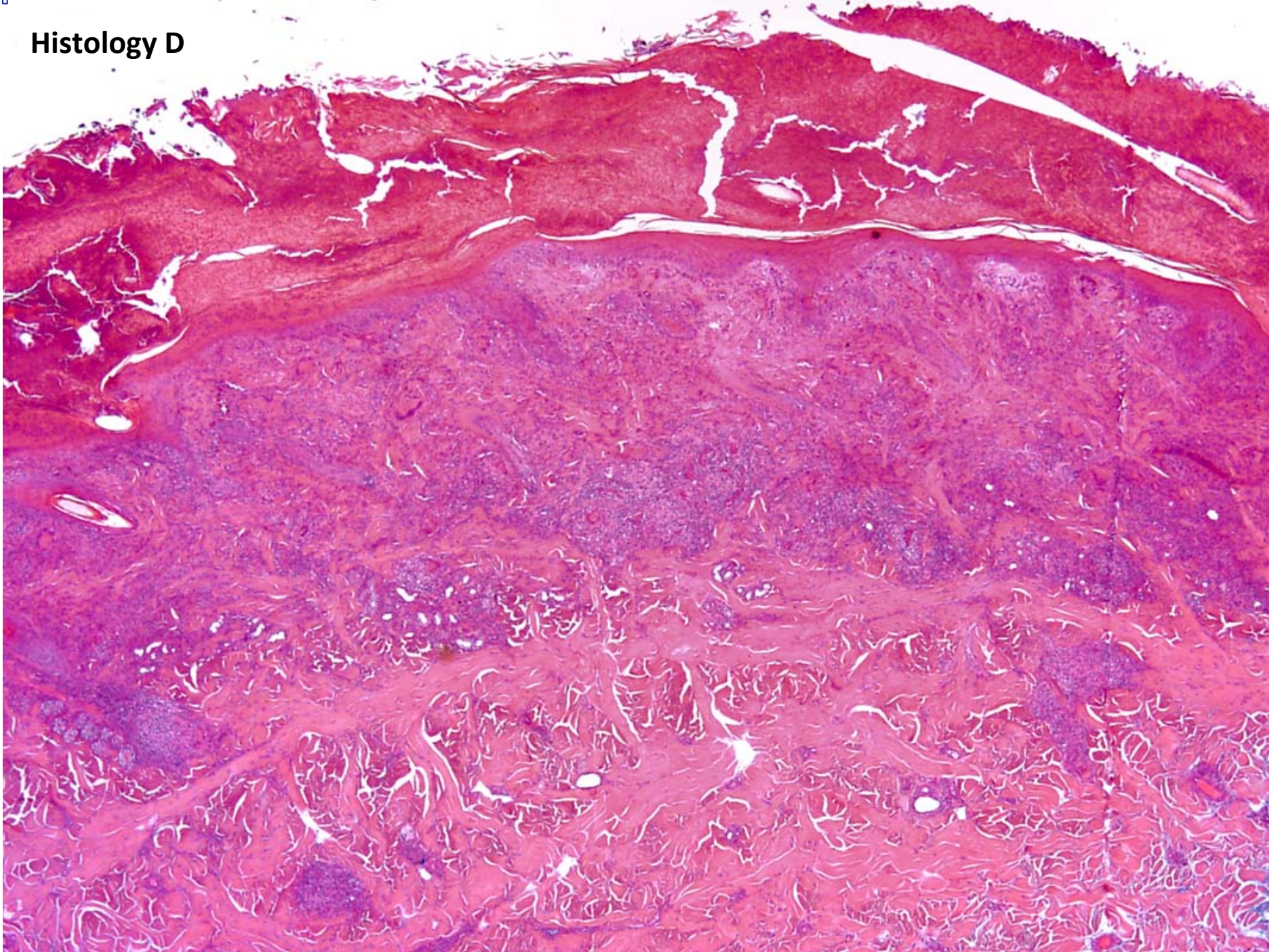
Histology D



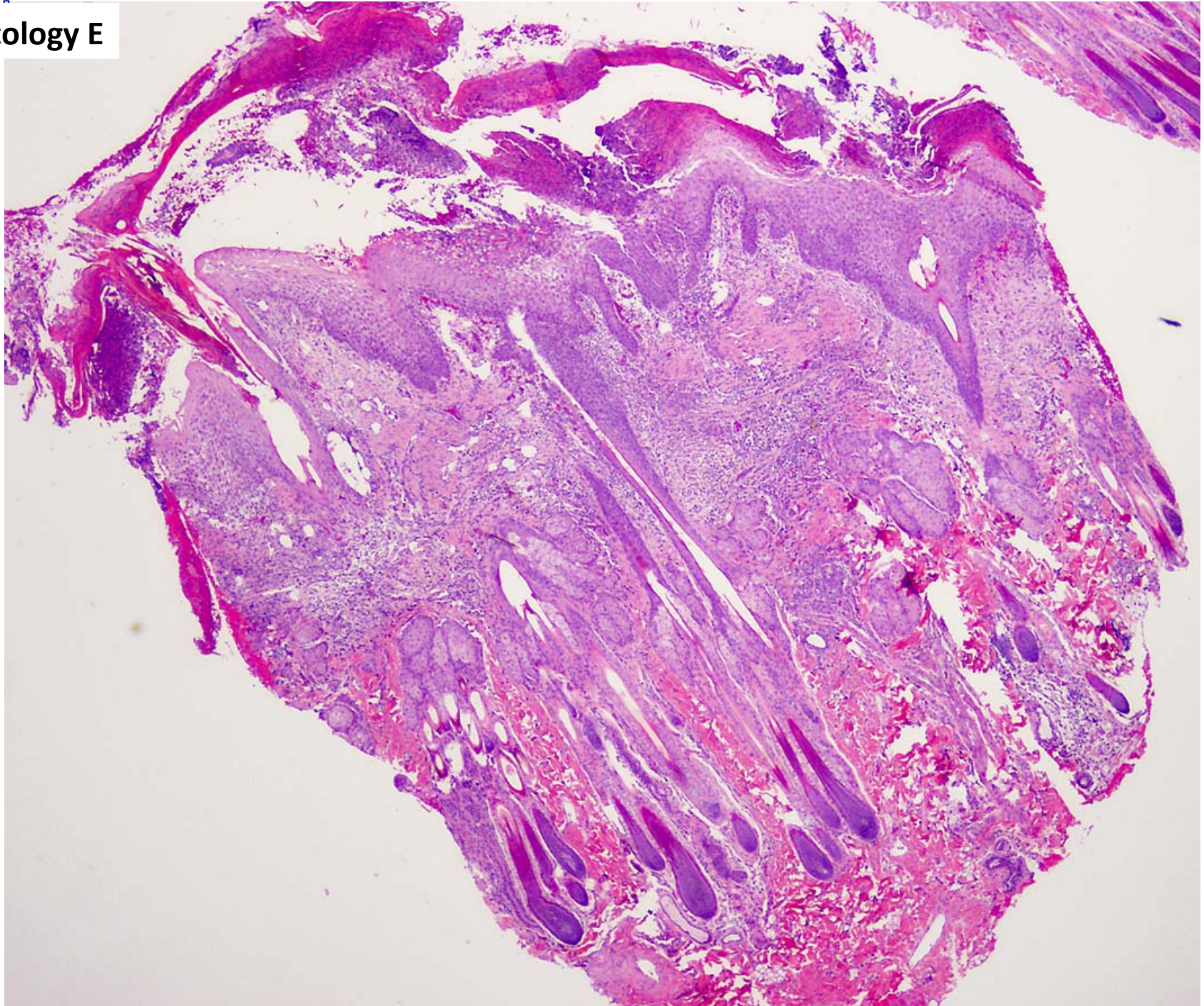
Histology D



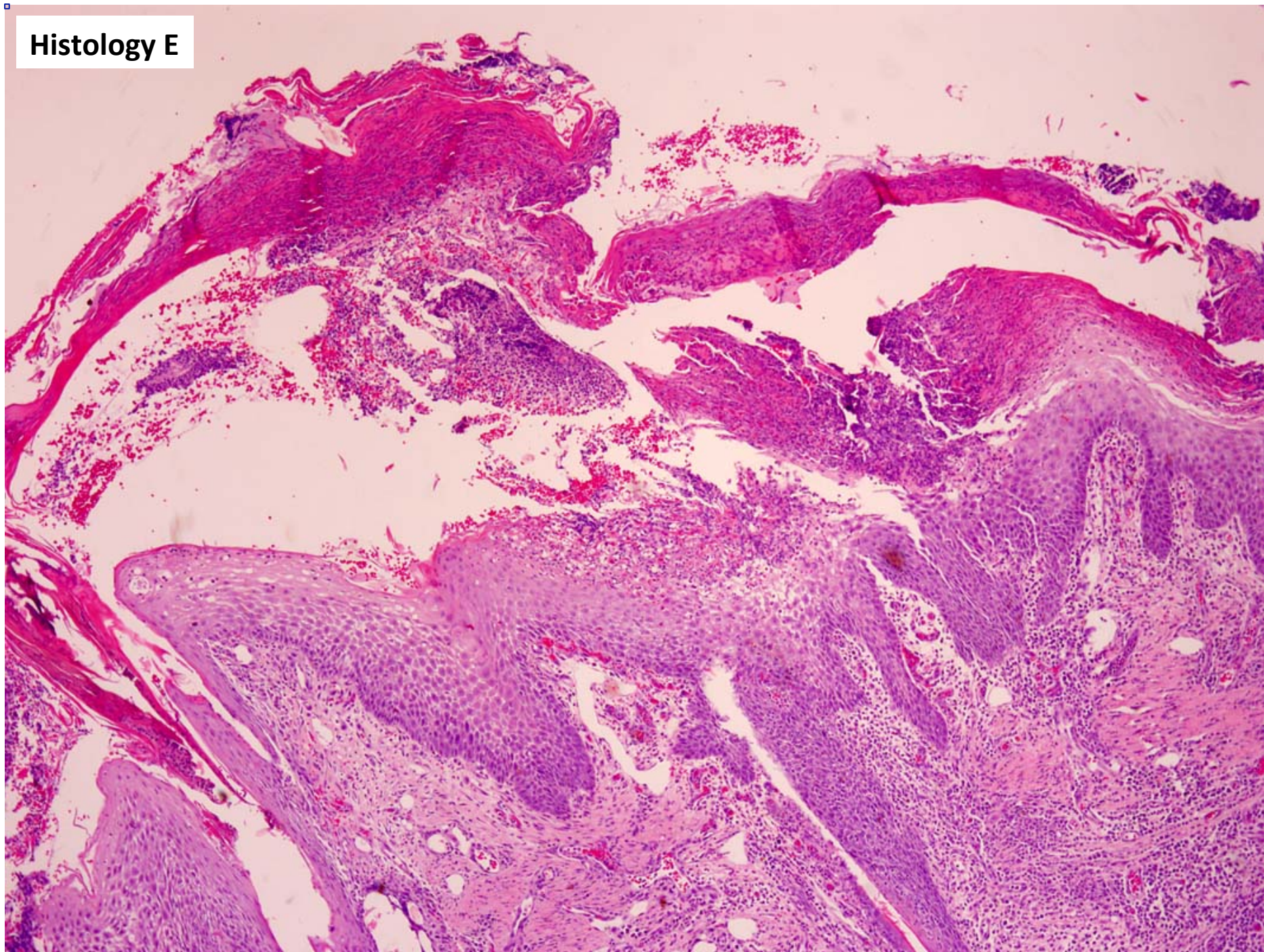
▣
Histology D



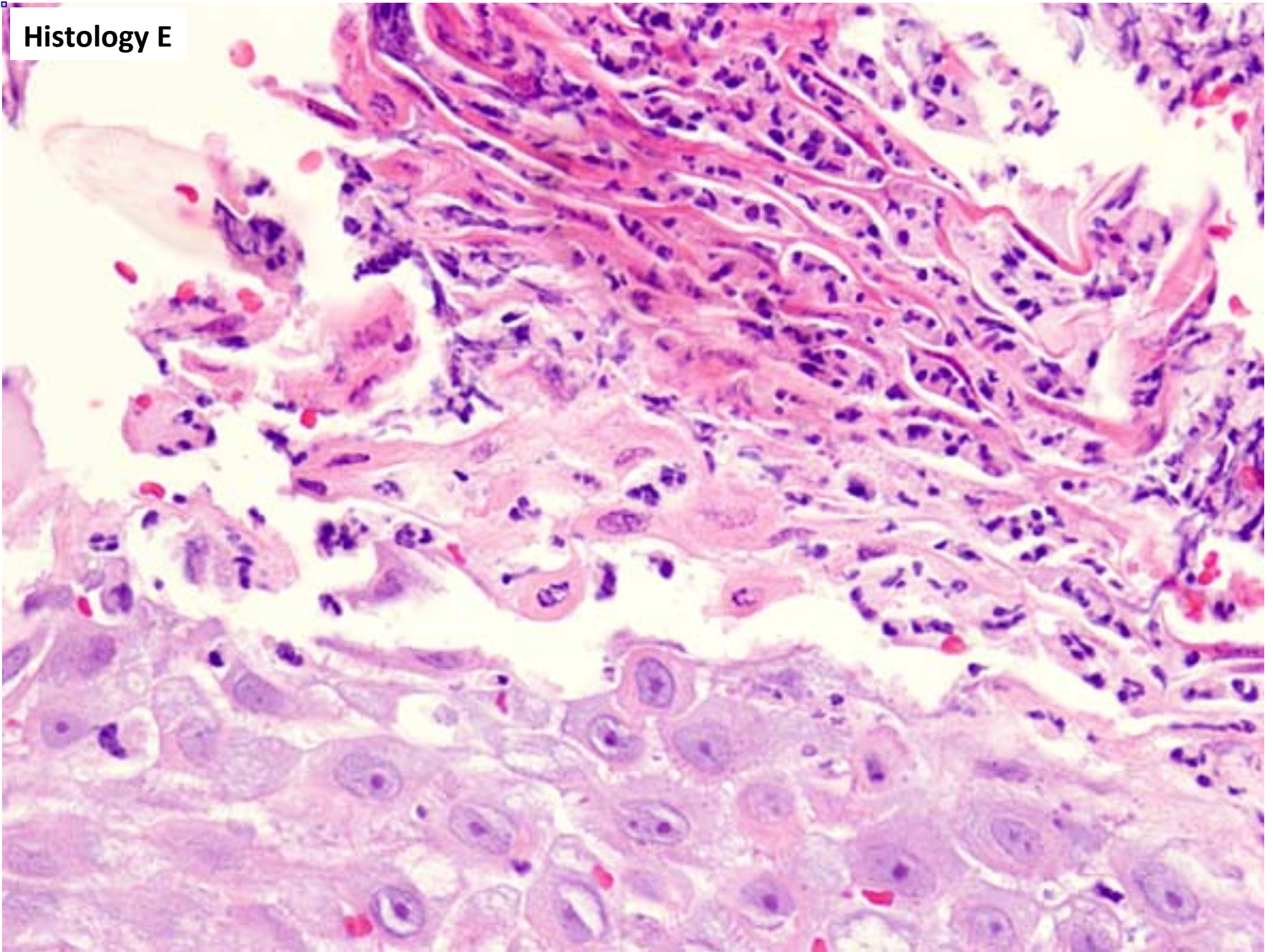
Histology E



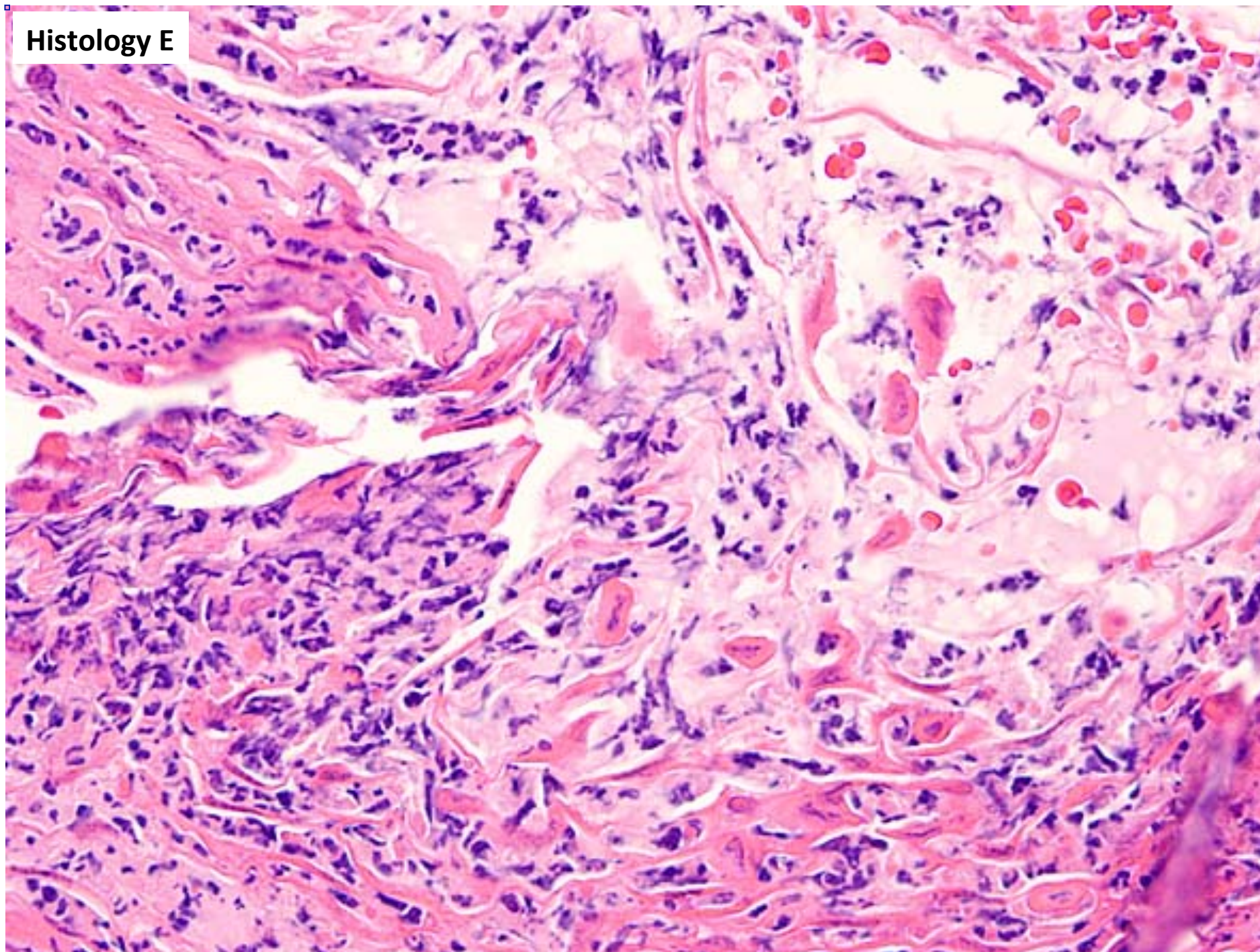
Histology E



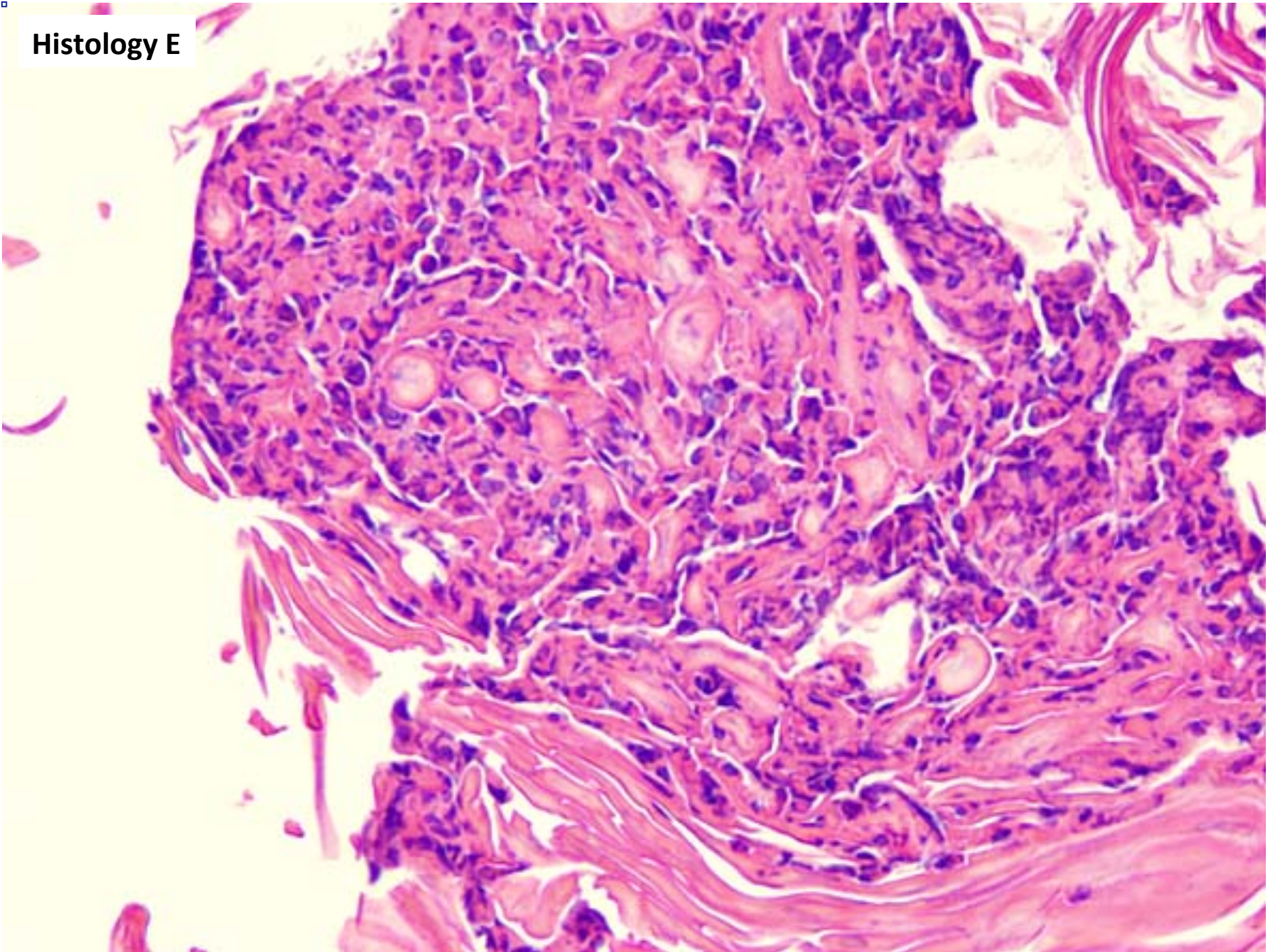
Histology E



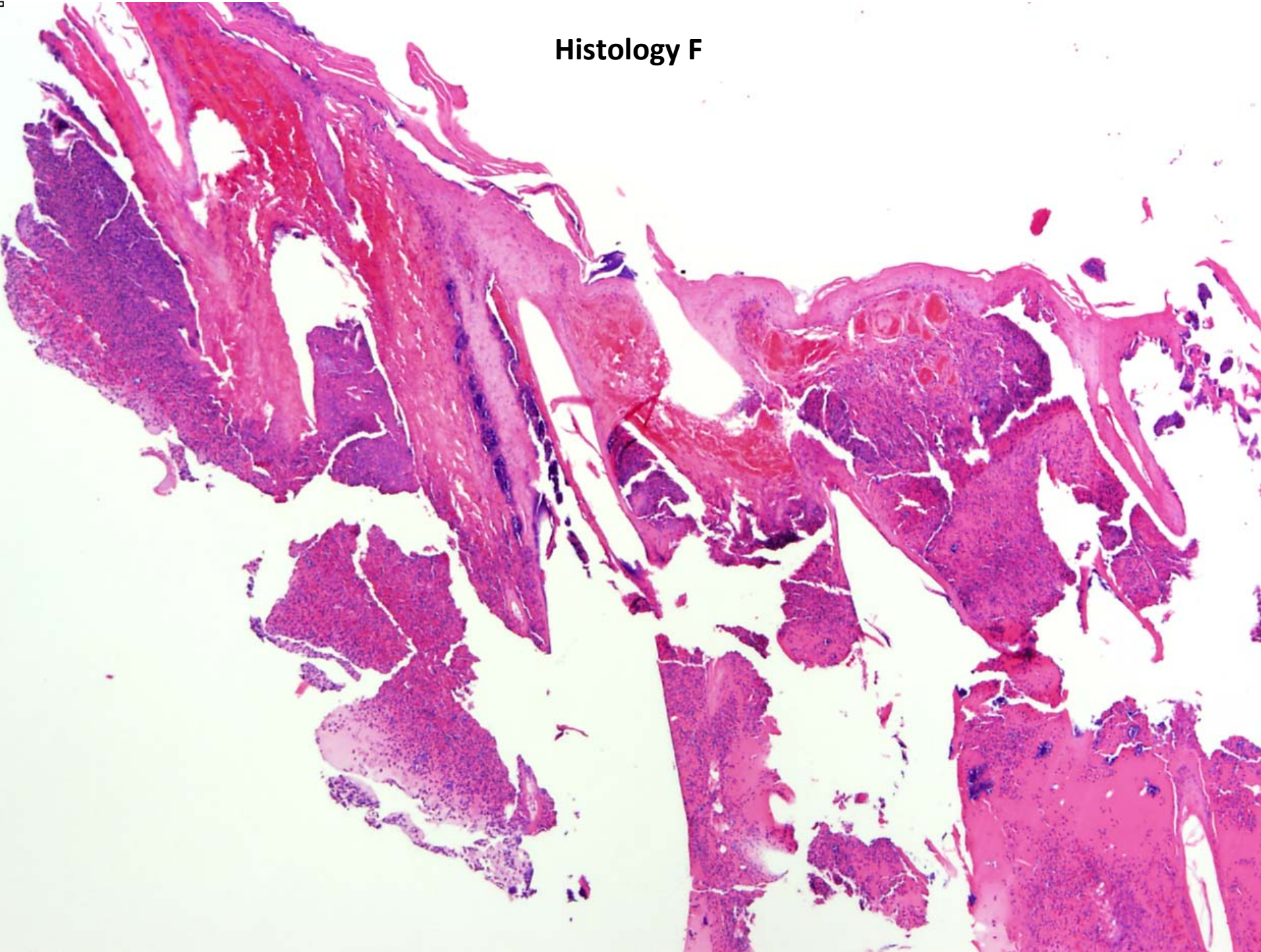
Histology E



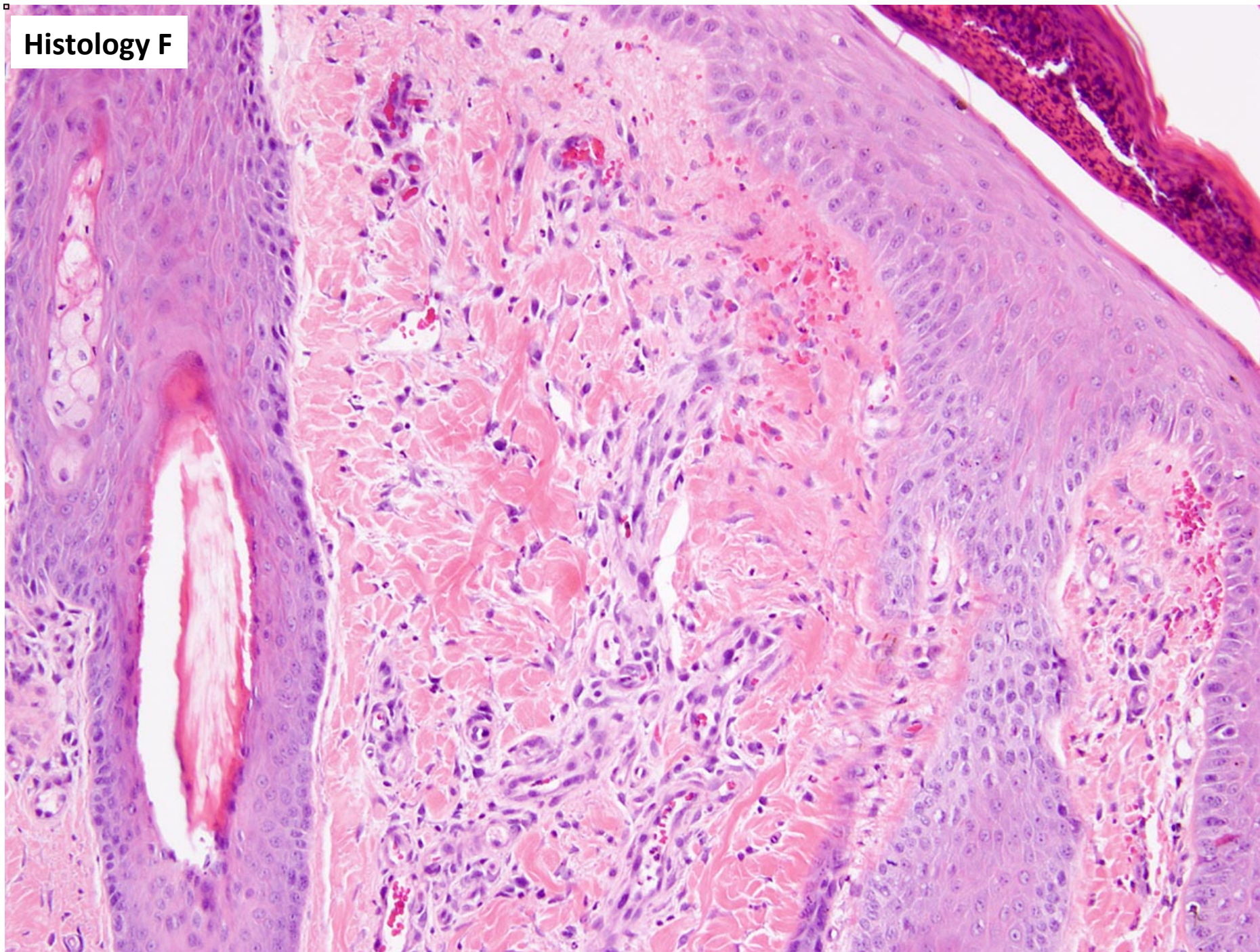
Histology E



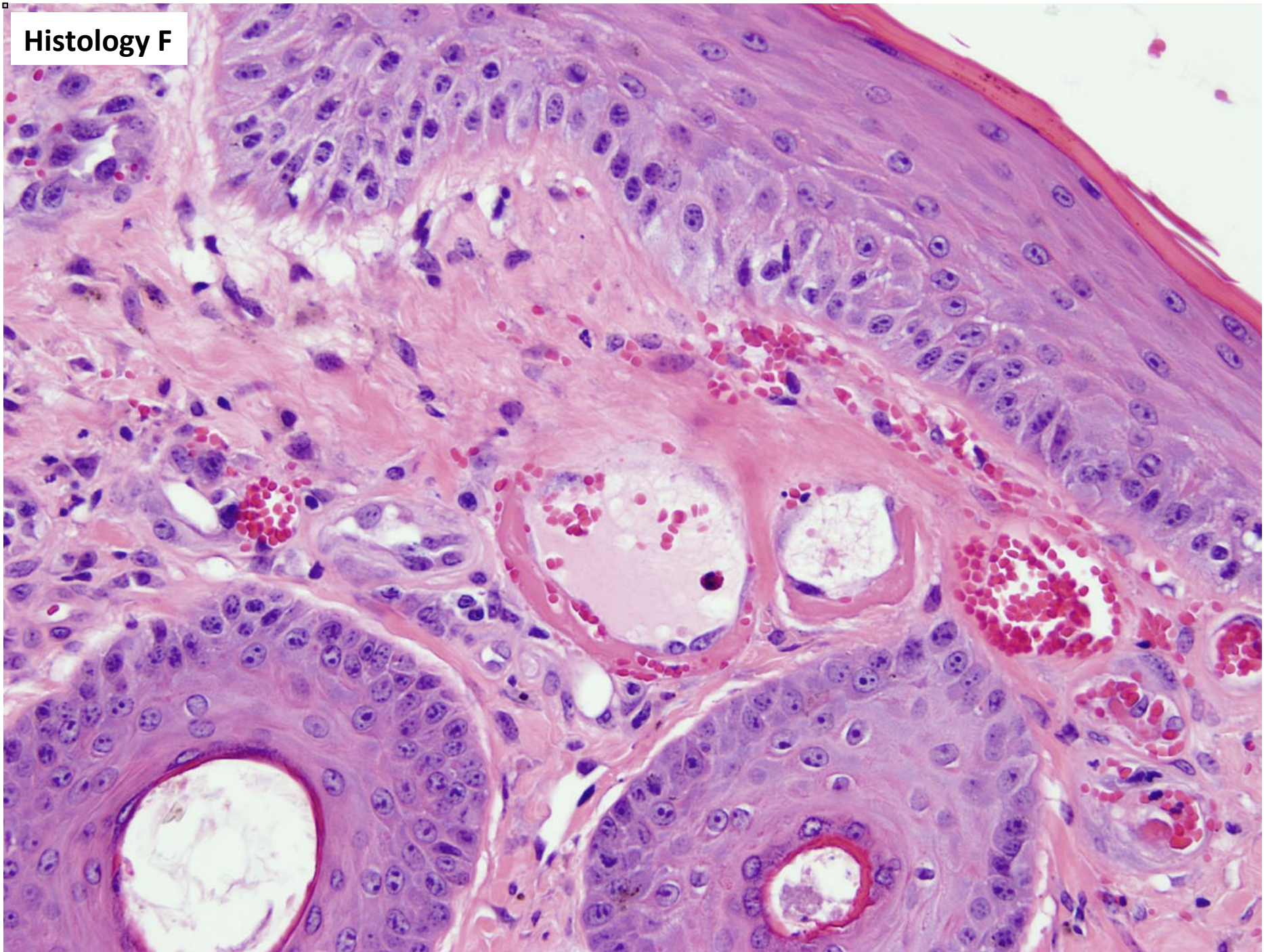
Histology F



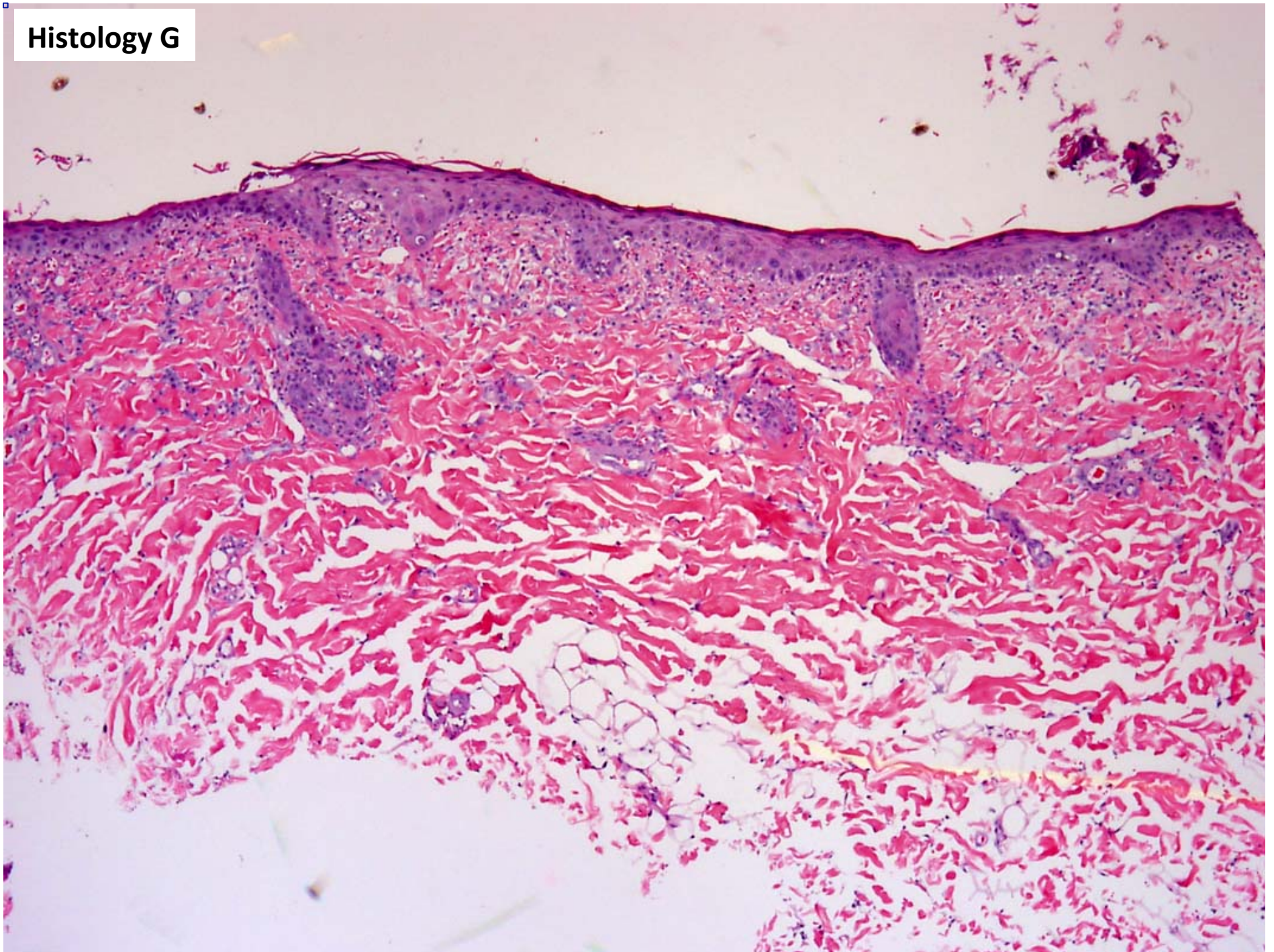
Histology F



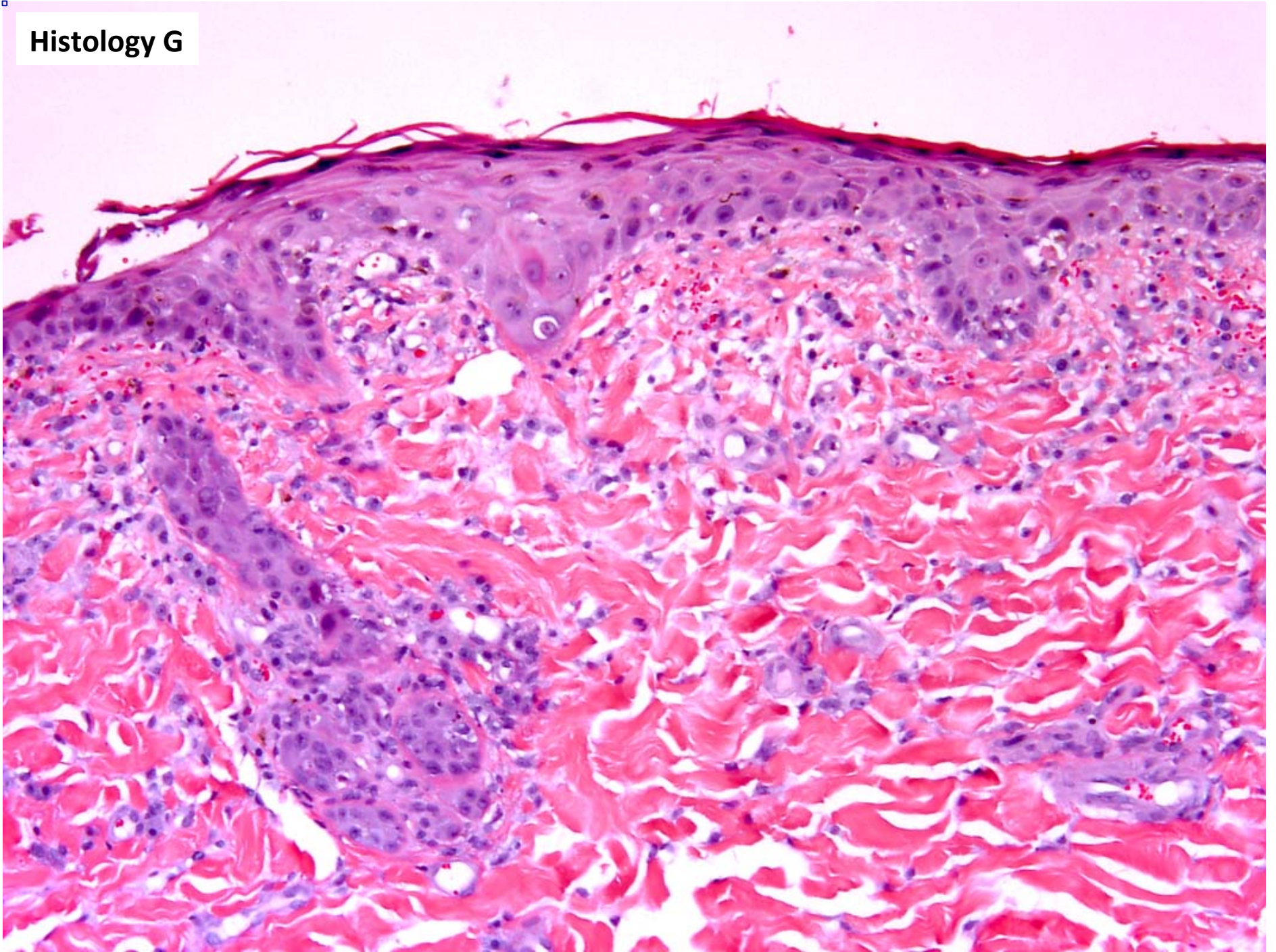
Histology F

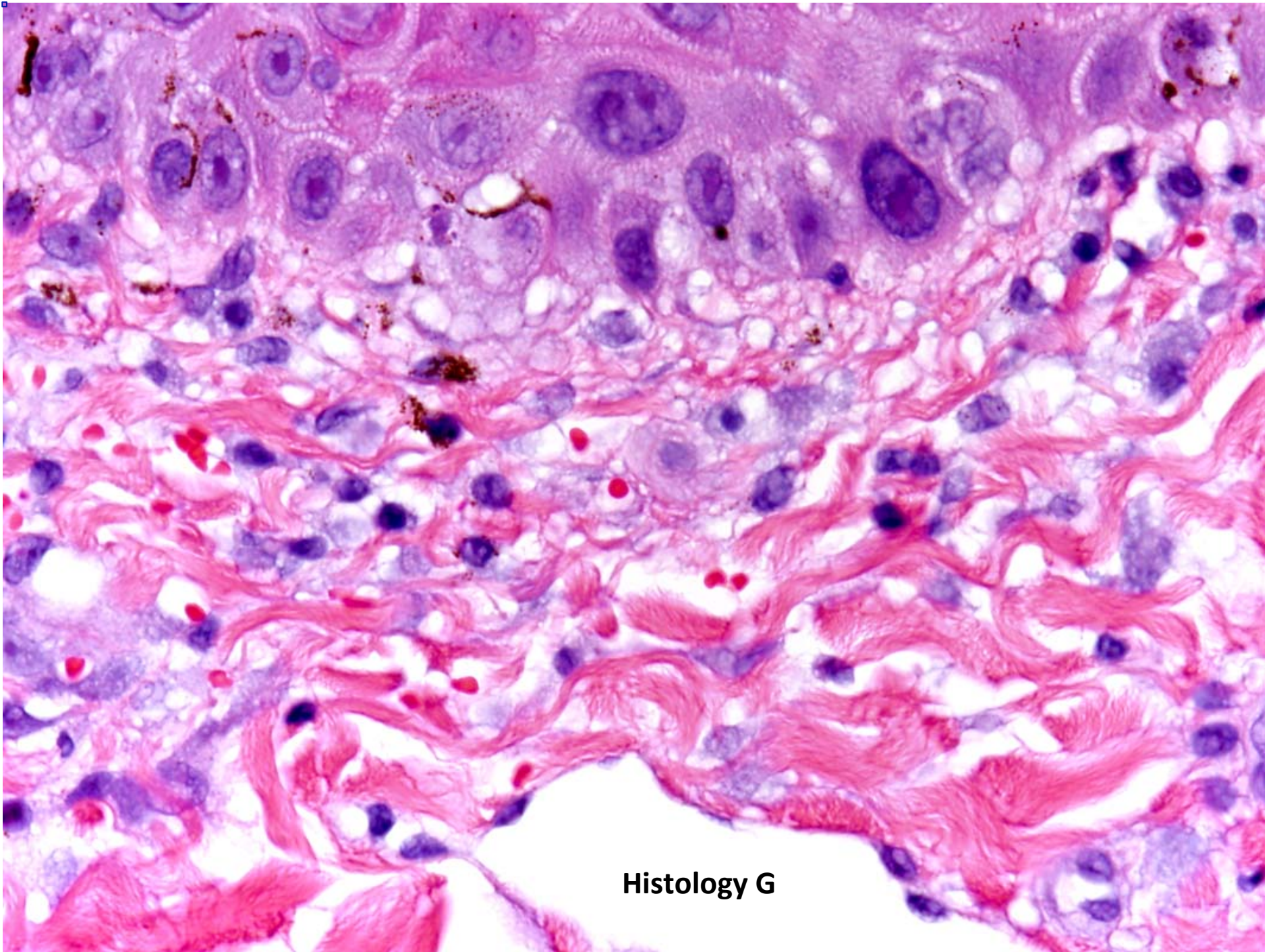


Histology G



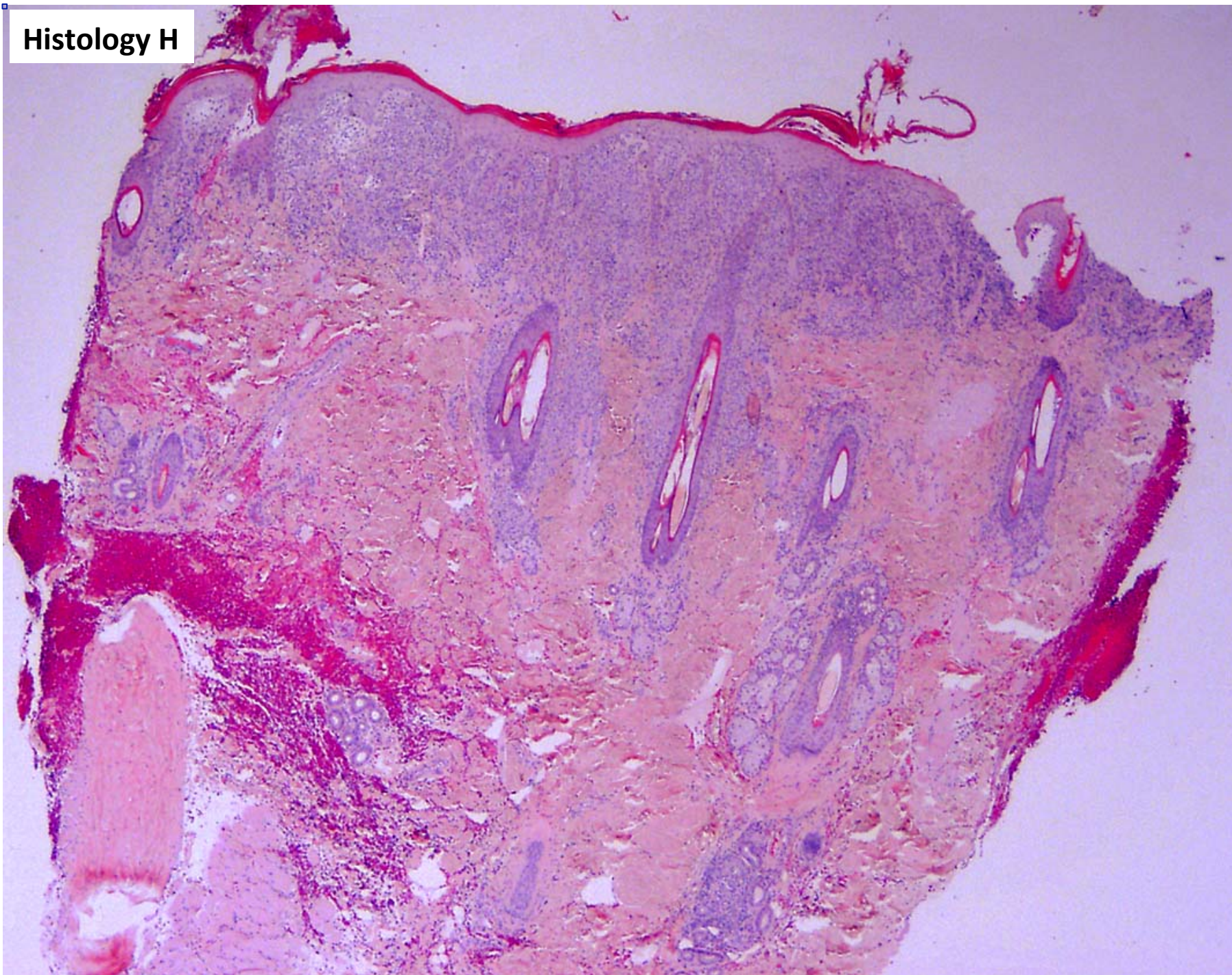
Histology G



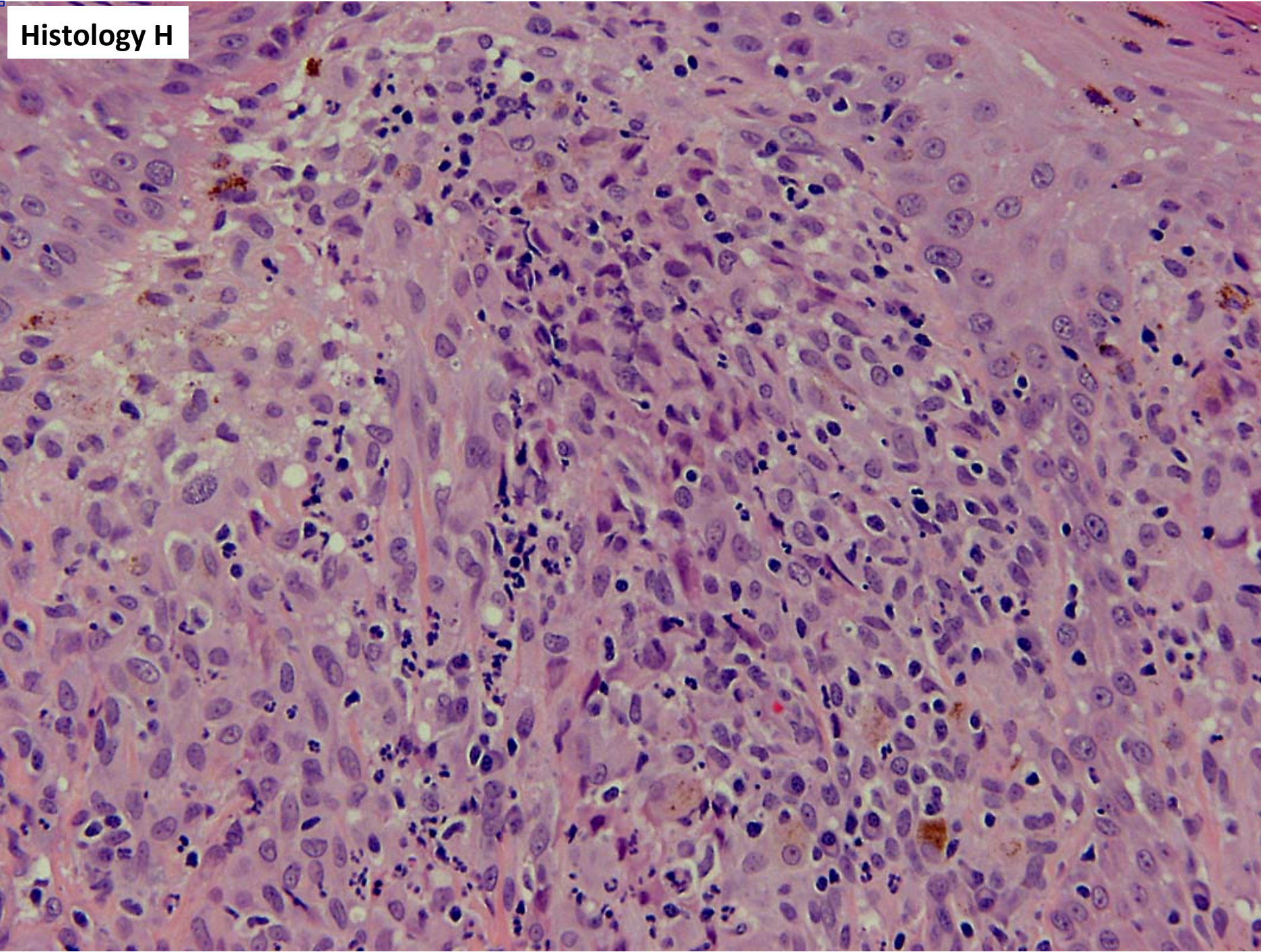


Histology G

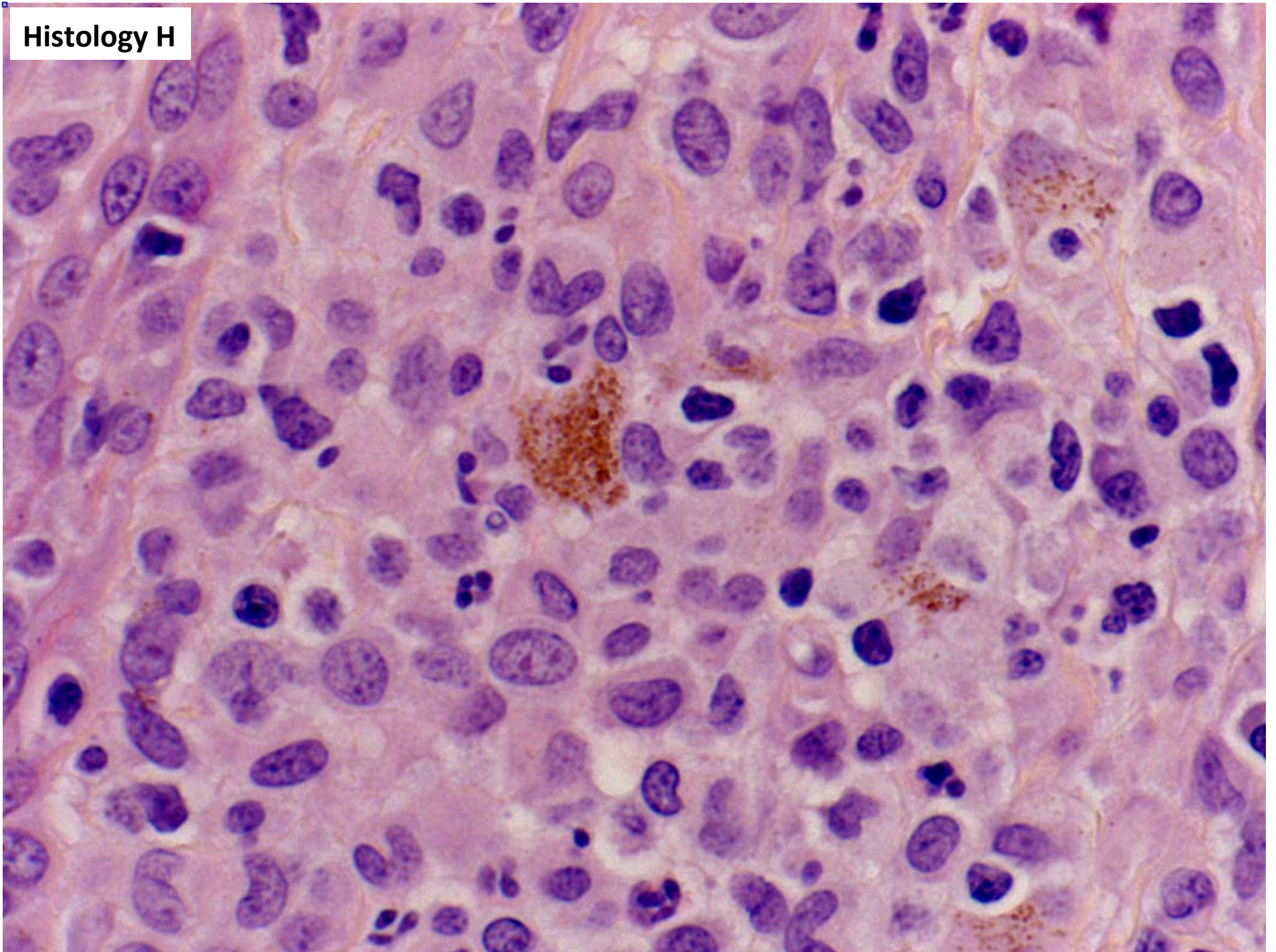
Histology H



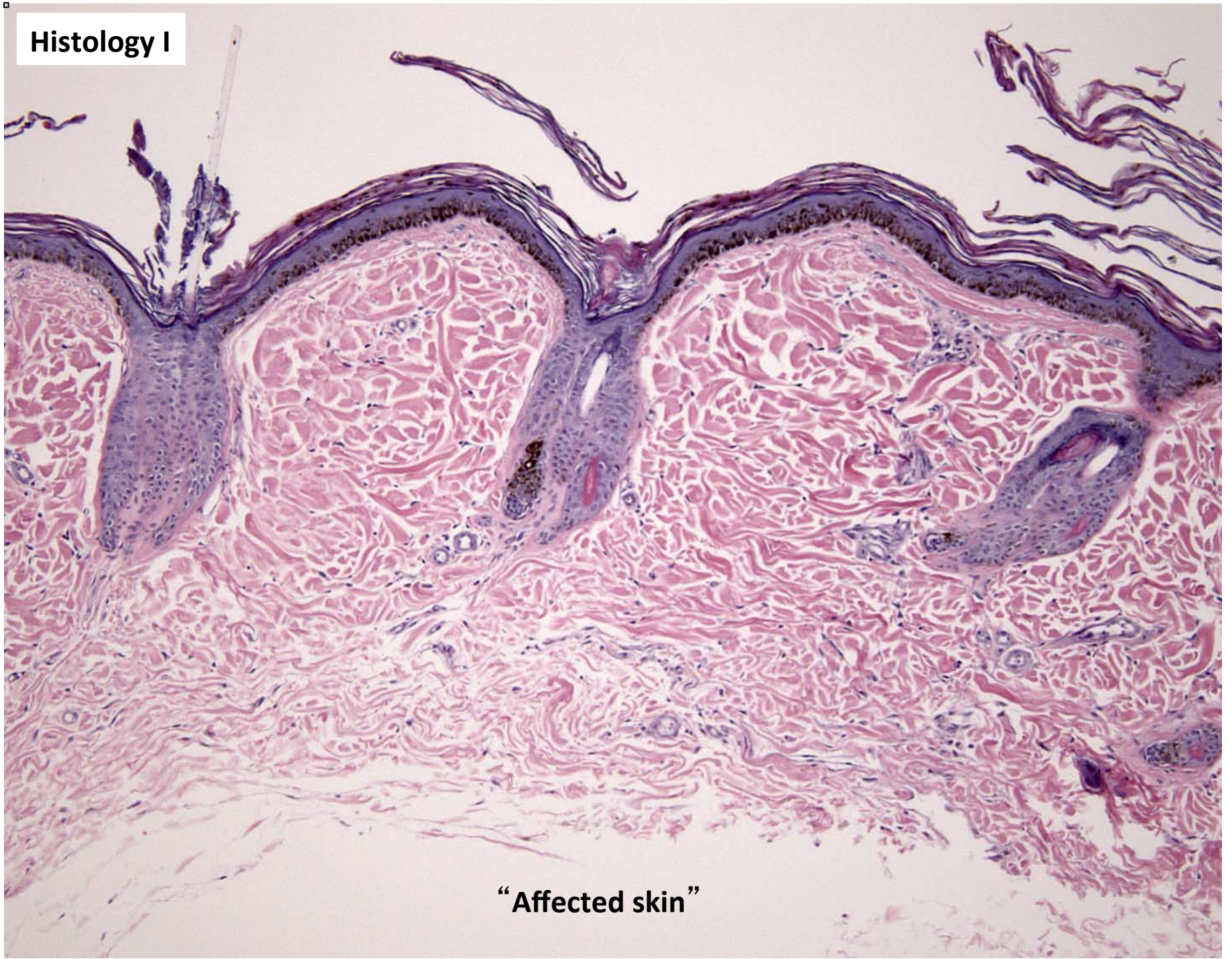
Histology H



Histology H

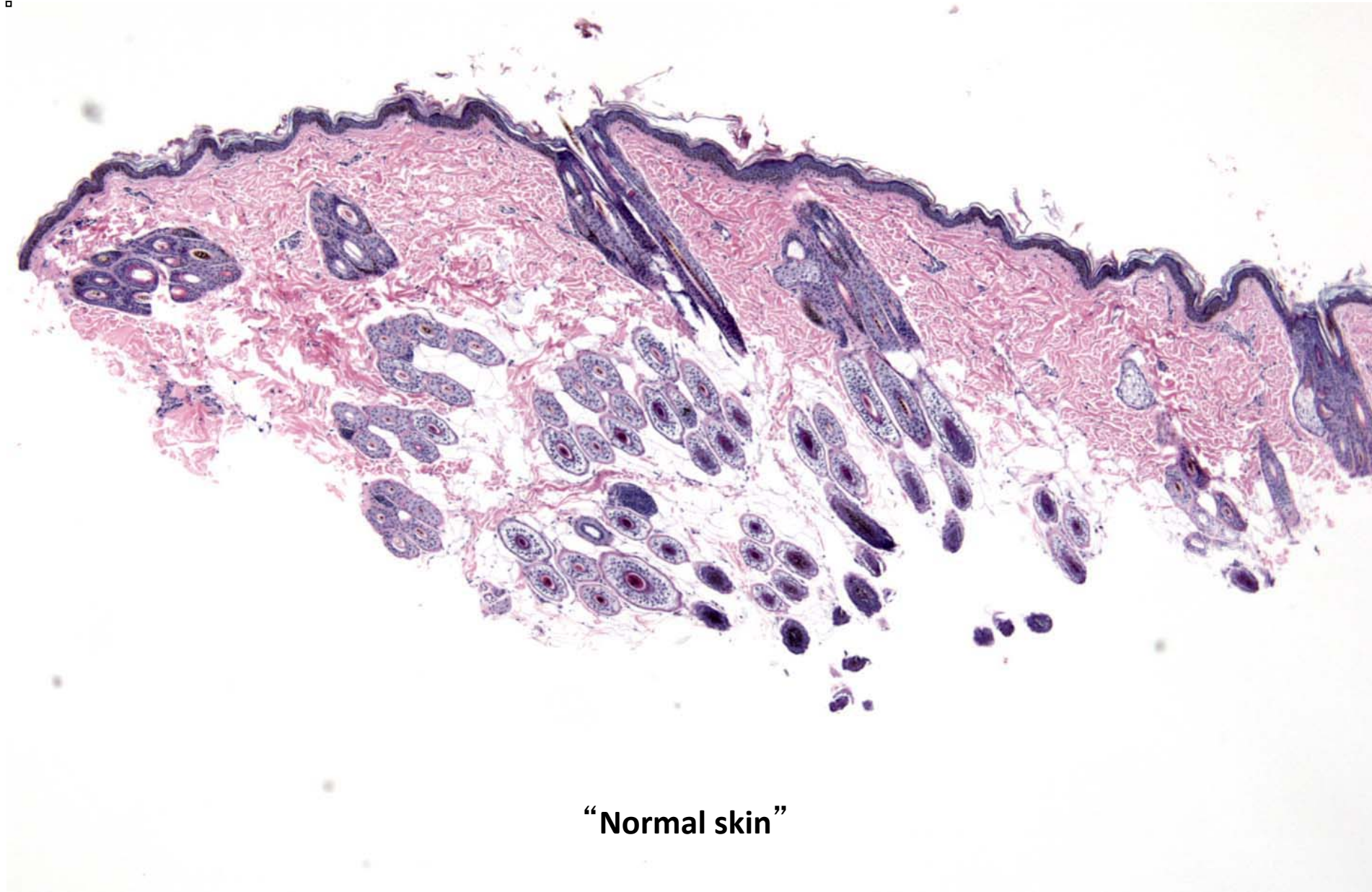


Histology I



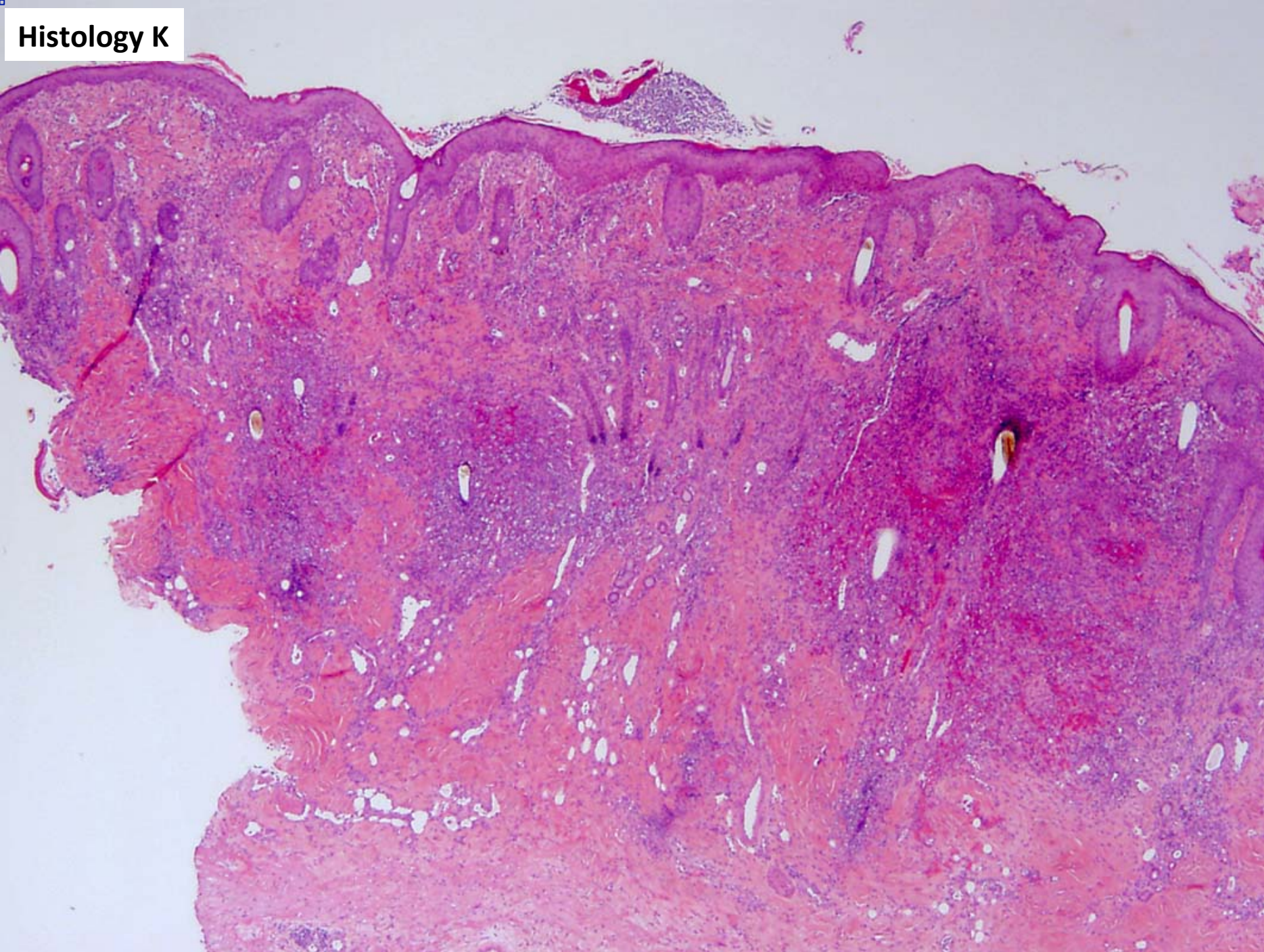
“Affected skin”

Histology I

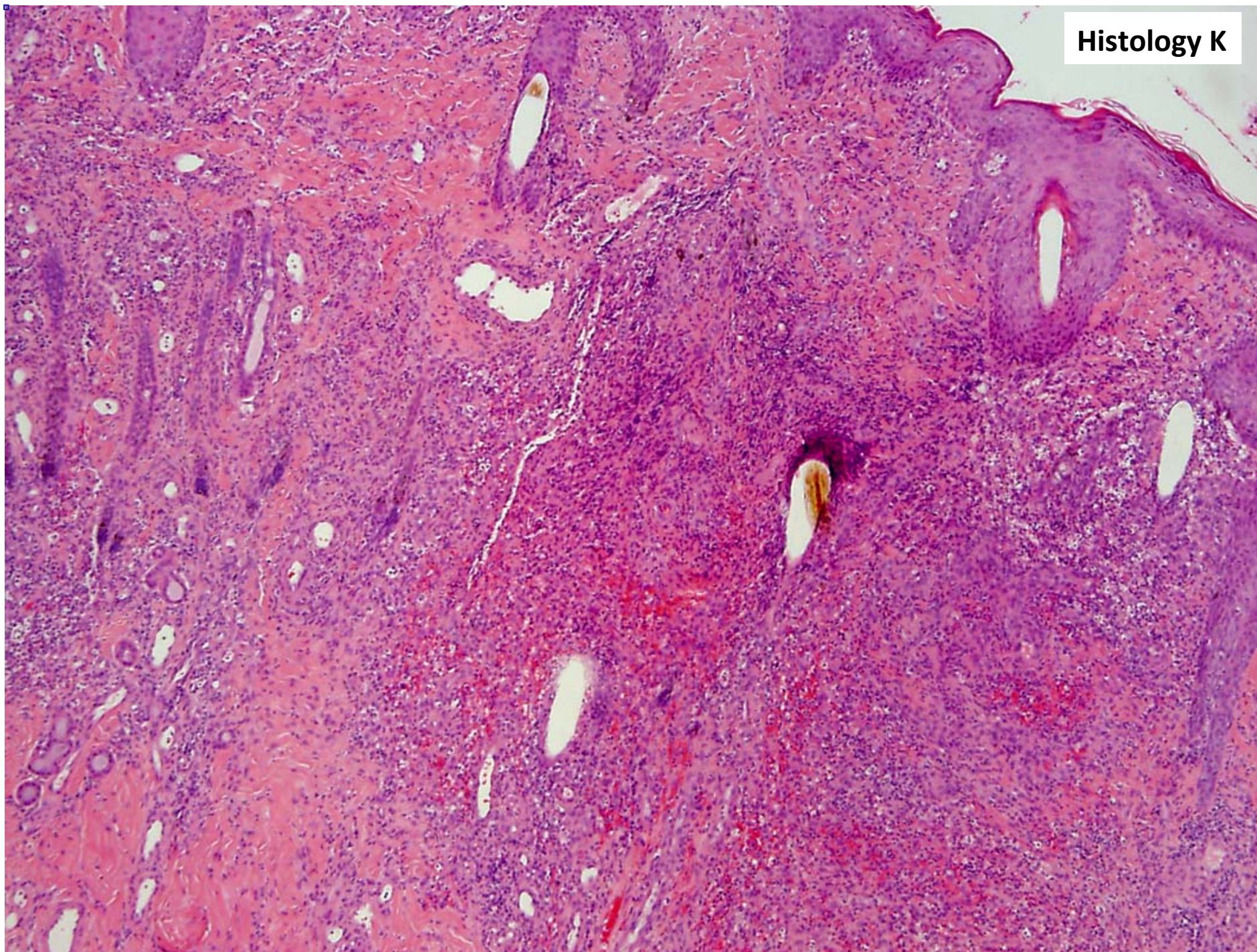


“Normal skin”

Histology K



Histology K



Histology K

